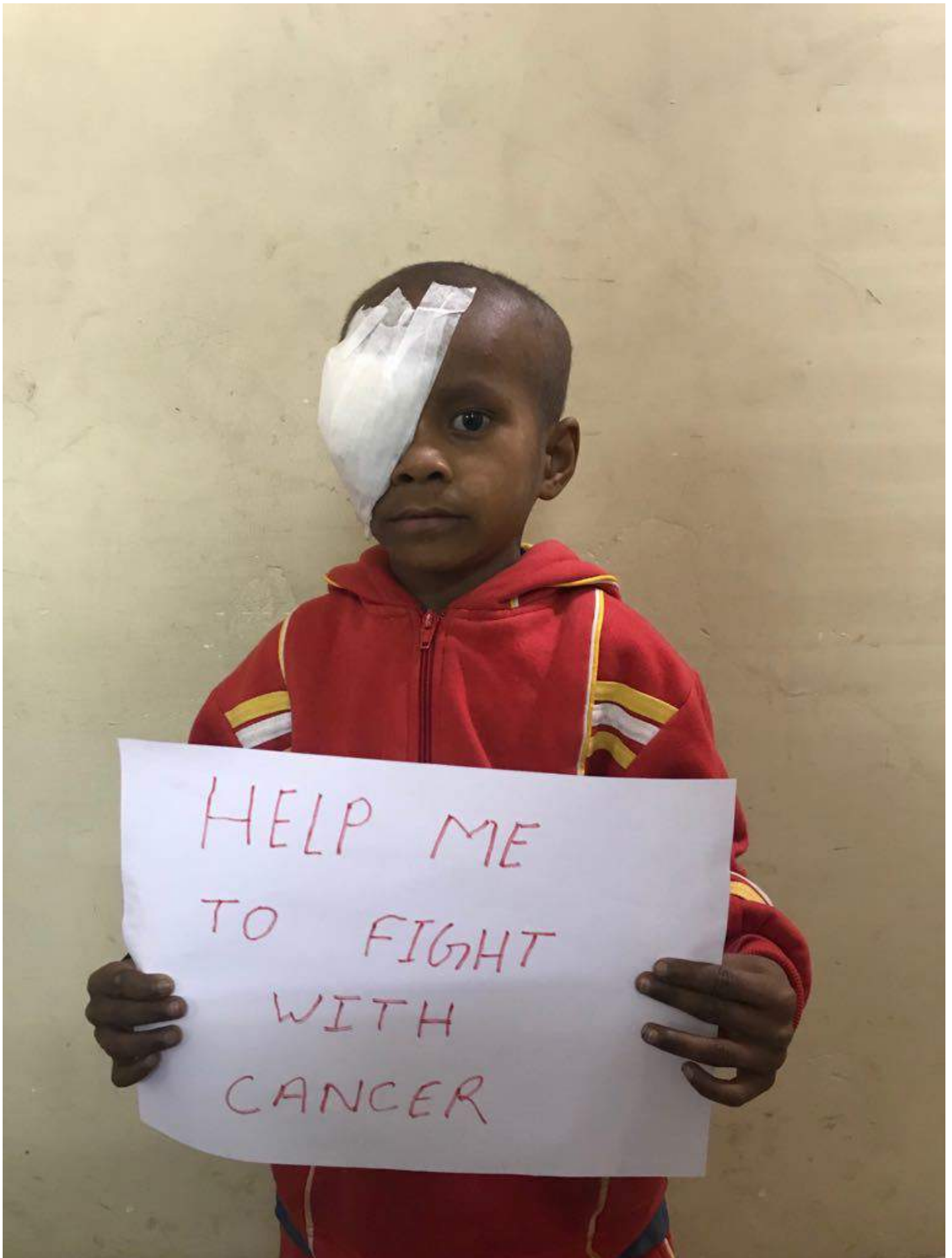



HELP ME
TO FIGHT
WITH
CANCER

दिनांक - Date

उपचार - Treatment

a Review with please

Kindly see FNAC report

28 APR 2017

Diagnosed

24/5/17

① Dressing & bandaged

follow up in RB clinic.

14/7/17

cls by unit 6 SR

② RMS ③ prescripted antibiotics

Adv

supp Augmentin 3ml
supp Digene 3ml BD
E/d Moxicy 4/4d

18/6/17

HPE report No (17-313)

Date of report - 1/6/17.

- IRCH / Paeds oncology opinion

Report : ④ orbital mass shows features of an all embryonal rhabdomyosarcoma. Immunostains for Desmin and myogenin are positive in the tumour cells.

#115

2 PM

Ms. Sophie
Kindly give report

नेत्र ईश्वरीय सर्वश्रेष्ठ उपहार है जिनका मनुष्य जीवन में दान करना परमश्रेष्ठ है।
इनकी पुर्ण रक्षा कीजिए ताकि ये आपकी रक्षा कर सकें।

Eyes are God's most precious gift to man kind. Take full care of them
So that they can take care of you

So that they can take care of you

30/8/17

Dressing done

11

9560728314

हृदय वक्ष एवं तंत्रिका विज्ञान केन्द्र
ब. से. वि.

अ. भा. आ. सं., नई दिल्ली-११००२९

Cardiothoracic & Neurosciences Centre, O.P.D.
A.I.I.M.S., New Delhi- 110029

दिनांक Date	PNS: E35, 2017 UHD: 102005942 Date: 13/04/2017 Mon, Thu	Dep't Neuro-Surgery
विभाग Deptt.	Name: RISHU KUMAR S/O: SIYASHAN PASWAN Phone No.: 7260020723 Consultant Room: 11 Dr. HITESH KUMAR	Age: 6Y 21D / Male
ब. से. वि. सं. O.P.D. No.	Dr. HITESH KUMAR	2
	Geography: Tue 9:30 AM - 10:30 AM Thurs/Fri Only: 11:00 AM - 2:00 PM	

01/04/2017

① Propranolol
VA ② ③
④ Minoxidil

Ⓡ Orbital SOL ? Rhabdomyosarcoma

DURGA MEDICOS
Medicine Dispensed
S. No. All-Medicine
On 14-04-17

Adv

Refd to RPC for Biopsy of lesion.
Plan to be decided based on biopsy report

R-11 ⑨

27/4/17

FNAC - slo metastatic tumor
Very large tumor. Surgical risk is Very high.

Attn: SANSAL

ब. रो. वि. कार्ड
O.P.D. Card

दृष्टि



ये अल्प वयस के बच्चे के लिए है

अनुभाग व दिन
Section and Day VI
बुधवार व शनिवार
Wednesday & Saturday

कमरा नंबर
Cabin No.

डा० राजेन्द्र प्रसाद नेत्र विज्ञान केन्द्र,
ज० मा० आयु० सं०, नई दिल्ली - ११००२९
Dr. Rajendra Prasad Centre for Ophthalmic Sciences
A.I.I.M.S., New Delhi-110029

यु एच आई डी संख्या
UHID No.

आचार्य राधिका टंडन का एकक
Prof. Radhika Tandon's Unit

रोगी का नाम Name of the patient	पुत्र/पुत्री/पत्नी S/D/W	लिंग Sex	आयु Age	पता Address
Rishi Kumar				

दिनांक DATE	निदान DIAGNOSIS
31/3/17	उपचार Treatment ? RMS @ orbit MRI 3/4 intra ocular extension.

ops to Paeds oncology

Adv. Refd to Paediatric Surgery / ophthalmology for biopsy @ 1/4/17
intra ocular extension
follow up - R Radha Seth.
@Dr. A

Adv. Surgery

① - Dressing of @ eye - for Paeds Dr. (Risk of Hye)

कृपया इस कार्ड को सुरक्षित रखें तथा अस्पताल में दिखाने के समय हर वक्त साथ लायें।
Kindly keep this Card safely and bring it on your follow-up visits.

१. धूम्रपान निषेध २. कूड़ा कर्कट केवल कूड़ेदान में ही डालें ३. थूकिये नहीं

ब. रो. वि. कार्ड
O.P.D. Card



अनुभाग व दिन
Section and Day VI
बुधवार व शनिवार
Wednesday & Saturday

कमरा नंबर
Cabin No.

DR. RAJENDRA PRASAD CENTRE FOR OPHTHALMIC SCIENCES

CHID: H068943
Dept. No.: 20170050039/86
RISHU KUMAR
NO. SHYAMSHAN PASWAN

Date: 08/04/2017
RPC OPD-Dr. Noopur Gupta
Cabin: VI
Room No.: 30
WED, SAT

Address: OPHTHALMIC POLICE BARPUR, BHAR, INDIA
Mobile: 7259010225



बि० रा
बि० रा
Dr. Raj
A.L.M.
यु एच
UHIC

एकक
on's Unit

पता
Address

दिनांक DATE निदान DIAGNOSIS उपचार Treatment

8 APR 2017

(32)

Dr. Bhavna, please

#344
Dr. Arshita

RAK Pediatric Oculogy opinion #2

RAK Neurology opinion #

F/o on Wednesday (11:30) pm

(63)
Bandage dressing etc

17/4/17

F/o in OPD Dr. Bhavna # (32) 9:00 am.

Dr. Arshita - IA

कृपया इस कार्ड को सुरक्षित रखें तथा अस्पताल में दिखाने के समय हर वक्त साथ लायें।
Kindly keep this Card safely and bring it on your follow-up visits.

१. धूम्रपान निषेध २. कूड़ा कंकट केवल कूड़ेदान में ही डालें ३. धुकिये नहीं

यू.के.य. नहा

दिनांक - Date

उपचार - Treatment

Ward 2A 17/4/12

syp Ebugesic 110p sos for pain

8.

18/00/12

flule Parammigeal RMS
E Eprolexis

Remin E pold's medicine

(62) Dressing for RLE.

18/00/12

नेत्र ईश्वरीय सर्वश्रेष्ठ उपहार है जिनका मनुष्य जीवन में दान करना परमश्रेष्ठ है।
इनकी पूर्ण रक्षा कीजिए ताकि ये आपकी रक्षा कर सकें।
Eyes are God's most precious gift to man kind. Take full care of them
So that they can take care of you

ब. रो. वि. कार्ड



अनुभाग व दिन
Section and Day I
सोमवार व बुधस्पतिवार
Monday & Wednesday

कमरा नंबर
Cabin No.

डा० राजेन्द्र प्र
अ०भा०आयु०स
Dr. Rajendra P
A.I.I.M.S., Ne
यु एच आई
UHID No.

DR. RAJENDRA PRASAD CENTRE FOR OPHTHALMIC SCIENCES

UHID: 38265594
Dept. No. 20170050039186
RISHU KUMAR 45/M
A/O: SHYAMSHAN PASWAN

Date: 10/03/2017 General 78
RPC OPD-Dr. SHORYA VARDHAN AZAD
Elate-I MON, THU
Room No.: 19

Address: GHE RASHAN POLICE HANGAR, BHAR, INDIA
Mobile: 7240031329



कक

पता
Address

रोगी
Name of the Patient

दिनांक DATE	निदान DIAGNOSIS	उपचार Treatment

30 MAR 2017

Ward 1A
Dr. Lomi
Dr. Divya

कृपया इस कार्ड को सुरक्षित रखें तथा अस्पताल में दिखाने के समय हर वक्त साथ लायें।
Kindly keep this Card safely and bring it on your follow-up visits.
१. धूम्रपान निषेध २. कूड़ा कर्कट केवल कूड़ेदान में ही डालें ३. धुकिये नहीं

CK-18293

21/10/17

Class: Adult Medical Oncology Clinic
 Dept: MEDICAL ONCOLOGY
 Name: RISHI KUMAR
 SIDA-SYASDAN PANDAN
 Phone No: 220020523
 Address: GHARSIAN POLICE STATION, BHANU, GUDA

ICD Code: 2382/2017
 UHID: 102685943
 Sex/Age: M/47
 Room: 31 (386) Morning

थान रोटरी कैंसर अस्पताल
 e Rotary Cancer Hospital
 A.I.I.M.S. HOSPITAL
 Patient Department
 PROHIBITED IN HOSPITAL PREMISES

OPR-6

199891

रजिस्ट्रार संकेत सं./O.P.D. Regn. No.

↓ SR

DOB-199891

DR. K.R.A. IICL, AIIMS, NEW DELHI

UHID: 102685943

Rishi Kumar

लिंग Sex	उम्र Age	जन्म तिथि/Date of Birth

रोग/Diagnosis

Orbital Embryonal Rhabd (CNSO)

दिनांक/Date

उपचार/Treatment

9/10

WRT # 15, 16, 17.

CT 9/10/17

4mg

2mg Celest 4mg } 100 wip (D1)
 2mg Dexa 4mg }

2mg VCR 1.2mg wpush → 9/10
 → 16/10
 → 23/10

2mg Actinomycin-D 0.85mg wpush → 9/10/17

2mg Cyclophosphamide 800mg wpush → 9/10

2mg Meona 600mg wpush D1 → 9/10/17

↓ कीमती व दवा

Tab Dexa 2mg Po BD 29/10/17 व 30/10/17 x 3 days

Tab J.Lanzol 15mg Po 30/10/17 व 31/10/17 x 3 days



डा. बी. आर. अम्बेडकर संस्थान रोटरी कैंसर अस्पताल
Dr. B.R. Ambedkar Institute Rotary Cancer Hospital

DR. B.R.A. BHILAINSI, NEW DELHI

OPR-6

ICD No. 109891

Reg. Date-04/05/2017

Clinic Adult Medical Oncology Clinic

Clinic No. 229022017

Dept. MEDICAL ONCOLOGY
General



Name RISHI KUMAR

UDD-02605943

NO. SHANSHAN PALMVA

Sex/Age MALE

Phone No. 729421023

Room 21 (Shift Morning)

Address GRIHSHAN PALICE HARPER, BHAR, INDIA

PREMISES

Regn. No.

Date BR/Date of Birth

एम्ब/Unit Asl
विभाग/Dept.
रोगी/Name

DR. B.R.A. BHILAINSI, NEW DELHI

Reg. Date-04/05/2017

रोग/Diagnosis

90 Orbital RMS

दिनांक/Date	उपचार/Treatment
6/7/17	CRK 6 VAC - CRK OK
	<p>3g Emet Aug } DL</p> <p>4g Dom Aug }</p> <p>2g VCR 1.2mg IVP DI, DB, DIS</p> <p>2g Actinomycin-D 850Mgms IVP DL</p> <p>2g Endoxan 800mg IVP DL</p> <p>2g Mesna 600mg IVP DL</p> <p>Postchemo 2g GCSF 75Mg SC x 5days</p> <p>Tab Emet Aug TDJ ---</p> <p>Tab Dom Aug TR 1Tab OD ---</p> <p>Tab Dom Aug RD ---</p>

form 15

~~DL~~
6/7/17

DL
DB
DIS

DL

3days

Alum.
13/3/17

CRK

अंगदान-जीवन का बहुमूल्य उपहार/ORGAN DONATION - A GIFT OF LIFE

O.R.B.O., AIIMS, 26588360, 26593444, www.orbo.org Helpline - 1060 (24 hrs service)

बाहर से आने वाले रोगियों के लिए धर्मशाला की सुविधा उपलब्ध है/Dharamshala facility is available for outstation patients

Room 59/12

21/7/12 - 23/7/12

9:00 - 5:00pm

PAS



- T. Emerck 8 4m 80
- T. DEAN 4m 1.0-1.5
- T. Longa Ja tas 1.5-2.0

≥ 100 F

3d

19/7/12

CT
21/7

2 VCR 1.2mg ivp. - Room 15

Take Date for CT Scan

Follow up on 24/7/2012 - check lab results

VCR 10/24/12
 120 31/7
 P15 1/7/12

24/7/12

week 9 VAC

CBC OK

Room 15

CT

24/7/12

as over leaf

2 GCSF 1.25 mg ivp 0D X-rays wof D3

RTU: 21/7/2012 @ 8 AM in CBC

• Photocopy of Barcode MRI.

• Take Date for CT Scan

• RT Review Tuesday/Friday @ 8 AM Room 9/10

by

by [Signature]



डा. बी. आर. अम्बेडकर संस्थान रोटरी कैंसर अस्पताल
The Rotary Cancer Hospital

DR. B.R.A. ICHLAUMS, NEW DELHI
 ICHH No. 198891 Reg. Date-04/05/2017
 Clinic: Adult Medical Oncology Clinic Clinic No. 239822017
 Dept.: MEDICAL ONCOLOGY
 General
 Name: RISHU KUMAR UHID-102682943
 S/O: AYASHAN PASWAN Sex/Age: M/37
 Phone No. 726000523 Room 58 (Shift Morning)
 Address: GHRASHAN POLICE HAZRAT, BHAR, INDIA

A.I.I.M.S. HOSPITAL
 Out Patient Department
 NO SMOKING PROHIBITED IN HOSPITAL PREMISES

OPR-6

इसके बिना पंजीकृत सं/O.P.D. Regn. No. 258

लिंग Sex	वय Age	जन तिथि/Date of Birth

रोग/Diagnosis

(Rt) Orbital RMS, non metast.

दिनांक/Date

58/11/17
30/11

उपचार/Treatment

wrct# 20. vte. (75%)

13/11/17

B.C.T
19/11/17

Adm

2q Eneset 4mg
2q Dopa 4mg } icip.

- 2q. vcr 0.9 mg ipush (D1)
- 2q. Actinomycin D 0.6mg ipush (D1)
- 2q Cyclophosphamide 500 mg ipush (D1)
- 2q mesna 300 mg ipush (D1)

Postchemo

Tas. Eneset 2mg po TDS
Tas Junior Loperidol 15mg po oo-o

2x1000 की
x2d.

अंगदान-जीवन का बहुमूल्य उपहार/ORGAN DONATION - A GIFT OF LIFE

O.R.B.O., AIIMS, 26588360, 26593444, www.orbo.org Helpline - 1060 (24 hrs service)

बाहर से आने वाले रोगियों के लिए धर्मशाला की सुविधा उपलब्ध है/Dharamshala facility is available for outstation patients

P.F.D.

Tas Dexa 2mg Po TDS \leftarrow (asmt in) x 3d.

2mg 4x/24 ~~50~~ 50 ug s.c oo x 5 days w-e of 05.

OPD. - 23/11/17 - (use)

$\frac{D_1}{10/11/17}$ $\frac{D_2}{20/11}$ ✓

SR

18/11/17

Dr. RJC casualty

(R) Dressing done.

SR

23/11/17

Adv.

inj. VCR 0.9 mg IV on

23/11

30/11

$\frac{D_1}{23/11}$ ✓

$\frac{D_2}{30/11}$ ✓

to give drug *SR*

pu on 24/11/17 : CBC
Hb / LFT

25/11/17

Sy Mafex 12gm BD

Sy Amoxic 200 mg OD

Sy Gest 25 mg for 3d x 3 days

Sy Supercin 6ml sos for fever for 4 days

$\frac{D_1}{29/11/17}$ ✓

$\frac{D_2}{27/11/17}$ ✓

$\frac{D_3}{28/11}$ ✓

$\frac{D_1}{29/11/17}$ ✓

$\frac{D_2}{27/11/17}$ ✓

$\frac{D_3}{28/11}$ ✓

To
Inchance
Blood bank
Kindly allow
10 PRB donation

30/11/17
PB take the file

$\frac{D_1}{29/11/17}$ ✓

$\frac{D_2}{30/11/17}$ ✓



डा. बी. आर. अम्बेडकर संस्थान रोटरी कैंसर अस्पताल
Dr. B.R. Ambedkar Institute Rotary Cancer Hospital

3/10/17

अ.भा.उ

Adh. Medical Oncology Clinic

33820017

बहिः अस्पताल के अन्दर



OPR-6

एक/Unit Med Onc
विभाग/Dept Dr. SR

नाम HISHU KUMAR
ID SHASHAN PASTWAN

UID 11110-102685943
Sex/Age M/47

रोग सं. 73440021

Shift 3 (Shift Morning)

Address CHURASHAN POCKET HARPOUR, BHILAI, INDIA

53/2/10

199891

Date of Birth

12/1/80
9/1/80

DR. B.R.A. HUGHES, NEW DELHI

UID: 102685943



रोग/ Diagnosis

Orbital Embryonal RMS / ENCS / VAC - due Case - wk 12

दिनांक/ Date

21/09/2017

wk = 12

Re-medication: Ig: Gemt - 4mg + Ig: Doca - 4mg i.v.p - Day 1.

Chemotherapy: Ig: VCR - 1.2mg i.v.p - Day 1 7/09/2017

8: Actinomycin D - 850ug i.v.p - Day 2

Ig: Cyclophosphamide - 200mg i.v.p Day 1

Ig: MESNA - 500mg i.v.p Day 1

Postchemo:

Tab. Doca 2mg (2x) x 3days.

Tab. J. Lenzol 15mg (2x) x 3days.

Ed. Emect 2mg x 3day.

Ig: G-CSF - 75mcg, Day 2 onwards (23/09/2017 onwards) x 5 days.

Get R1 - spinosartan

Pls take the R1

R/v on 14/09/2017 c/cg/RF7

58/14
21/11
C7
21/8/17

Room NO 59/12
9:00 - 5:00pm
21/11 - 23/11/17

21/2/17

137
25/8
25/8
26
29/8
26/8
25

22/08/17

fever
- ded oral intake

PS-1
- Pulse - ok
- Chest
- Ws
- P/A

AMBEY MEDICINE CORNER
S.H. NEW DELHI-110029
Date: 20/8/17 For: 5/3/14g
Days Bill No:

Adv.

CBC

Syfi. Augmentin 500mg TDS
(500mg/125mg)
Syfi. Pen 500mg SOS
Review with (ASC)

21

24/09/2017

Wk = 12/Day - 25. Did not look very well.
- RT opinion - Did not look.

Go as Outpat. Cyclophosph - 400mg i/v Day 1/2
MESNA - 300mg i/v Day 1/2

ZiVER - 1mg i/v Day 1 (14/09)
Day 2 (15/09)
Day 3 (16/09)
J. Actinomycin D 50 mcg i/v Day 1 (14/09)

Zi. ACAG-CSF
25mg, S.C. 00
(Day 4 onward)
x 6 days

R. on 05/10/2017 i/v CSF well

D107
14/9/17
D207
15/9/17

27/09/17 - no NA (in 6 N by??)

Syfi. Ibuprofen 500mg tds 00

Syfi. Pen 500mg tds 00

Syfi. Augmentin (500mg) 1 tds tds 00

3d
05.1



डा. बी. आर. अम्बेडकर
Dr. B.R. Ambedkar

अ.भा.आ.सं.

बहिरंग रोड

अस्पताल के अन्दर धुआँपा

Dr. B.R. Ambedkar, NEW DELHI

ICCH No. 199881

ICCH No. 199881

ICCH No. 199881

ICCH No. 199881

ICCH No. 199881

ICCH No. 199881

ICCH No. 199881

ICCH No. 199881

Reg. Date: 06/03/2017

Class No. 21952/2017



11115-102687943

Sex/Age: M/6Y

Room No. (568) 15-0000

Address: CHIRAGANJAN POLICE BARRACK, BHILAI, INDIA

OPR-6

एक/Unit
विभाग/Dept.

नाम/Name

Rishi Kumar

FRONT/DOOR

SEX

M

AGE

6yr

of Birth

बिधा/Diagnosis

Orbital RMS

दिनांक/Date

29/6/13

उपचार/Treatment

Sy VCR 1-2mg IVP DL wof 29/6/12

Sy GCSF 75 mg IV x 3 days wof 29/6/12

HLU on 6/7/2012 @ 9 AM i CRK

- fever for caution - Room (58) Emergency OPD
- ORS (1 packet + 1 liter of water) Sol for transmission
- Syp Timosic 3 TDS TDS

Cy 29/6/13
OK to give
29/6

by hand

अंगदान जीवन का बहुमूल्य उपहार/ORGAN DONATION - A GIFT OF LIFE

O.R.B.O., AIIMS, 26588360, 26583444, www.orbo.org Helpline - 1060 (24 hrs service)

बाहर से आने वाले रोगियों के लिए धर्मशाला की सुविधा उपलब्ध है/Dharamshala facility is available for outstation patients



Rotary Cancer Hospital
I.I.M.S. HOSPITAL
Patient Department
SITUATED IN HOSPITAL PREMISES

3/10/17
OPR-8

Dr. BRA, IRCH NEW DELHI
Clinic: Adult Medical Oncology Clinic
Dept: MEDICAL ONCOLOGY
General
Name: RISHI KUMAR
NIC: SITASHAN PASTAN
Phone No: 750020523
Address: CHIRASHAN POLICE HARBOR, BHAK, INDIA

Reg. No: 01092017
Clinic No: 229822017
UHD: 102682941
Sex/Age: M/57
Room: 10 (Shift Morning)

पंजीकृत सं./O.P.D. Regn. No. RT-923

लिंग Sex	उम्र Age	जन्म तिथि/Date of Birth

रोग/Diagnosis: RMS

दिनांक/Date	उपचार/Treatment
<u>10/08/17</u>	ay. VC.R 1.2mg IVF. <u>10/08/17</u> <u>17/08/17</u>
<u>21/08/17</u>	• RTopinion Tue, /Fri Room no. 5 8:00 AM • F/U on 21/08/17 9:30 AM Room no. 13 CBC
<u>18/8/17</u>	To register RT-II OPD on 25/8/17 File to (2)
<u>3/10/17</u>	clo to Dr. Anupam Bswar (RT) admitted RT 45 wyl 25 #/5 wks ↓ [21 2 18] DPRT → RN 40 for date Continue chemorx (VAC) till wyl 3

Dr. P. Prakash
Dr. Lalit
3/10/17
please help
9/10/17

अंगदान-जीवन का बहुमूल्य उपहार/ORGAN DONATION - A GIFT OF LIFE
O.R.B.O., AIIMS, 26588360, 26593444, www.orbo.org Helpline - 1060 (24 hrs service)
धरमशाला की सुविधा उपलब्ध है/Dharamshala facility is available for outstation patients
PAC clearance (RM 60)

2/11/12

To cu on 9/11/12

[Handwritten signature]

[Handwritten signature]

9/11/12

Arystaric contract LA tabs

[Handwritten signature]

2.1 kg:

13/11/12

ck report - ok

kindly - giving duplicat. files.
issue.

30
Jan 10



डा. बी. आर. अम्बेडकर संस्थान रोटरी कैंसर अस्पताल
Dr. B.R. Ambedkar Institute Rotary Cancer Hospital

अ.भा.अ.
वहिन

OPR-6

रूम/Unit

DR

विभाग/Dept.

नाम/Name

DR. B.R.A. BIC/AIIMS, NEW DELHI

ICCH No. 199891

Reg. Date: 06/05/2017 3

Chief: Asst. Medical Oncology Chief

Case No. 23952/2017

Dept.: MEDICAL ONCOLOGY

General



Name: RISHU KUMAR

UHID-102655943

MO: DIVYANAN PASWAN

Sex/Age: M/67

Phone No. 730022923

Room 58 (Shift Morning)

Address: CHILKARAN POLICE HARPUR, BHASKAR, INDIA

1/Date of Birth

रोग/Diagnosis

90 (R) orbital mass for Evaluation

दिनांक/Date

उपचार/Treatment

8/6/17

H/E 90 of Myxoma

Plan

To discuss with Dr. Jeeva Karhgap

Further check after ~~1000~~ Discussion

H/O on 15/6/17 @ 9 AM to check

by hand

- ORS Packet in 1 liter of water 500
- Syrup Timivic 5ml TDS 2-3 times

By fever come to room (58) Emergency 019

अंगदान-जीवन का बहुमूल्य उपहार/ORGAN DONATION - A GIFT OF LIFE

O.R.B.O., AIIMS, 28588360, 26593444, www.orbo.org Helpline - 1060 (24 hrs service)

बाहर-से आने वाले रोगियों के लिए धर्मशाला की सुविधा उपलब्ध है/Dharamshala facility is available for outstation patients

15/6/2017

Wk 2 VAC

check ok in ~~box~~

- 2g Emset 4mg } D1
- 2g Dexa 4mg }

51/5
16/6

- 2g VCR 1.2mg 1VP D1 | D2 | D14

- 2g Acthion 850 Mfu D1

- 2g Endoxan 750 mg 1VP

- 2g Meme 450 mg 1VP

2g GCSF 7500 Mfu 3L x 5 days wof (D5) D

Postchemo

- Tab Emset 4mg 1/2 Tab T.D.S. } 5 days
- Tab Dexa 4mg 1/2 tab B.D. }
- Tab Lasolol 2R 1 Tab O.D.

RT Review Dr DN Sharma - Room 4 Tuesday/3rd day 8:30 AM

Hu m. 29/6/2017 @ 9 AM E CBC

extra

Proxy visit/Gilbert Scan in Mloward

missed Day 7 of vac.

Give D2 VCR will decide D4 in OPD

↳ form (15)

My friend JL

extra

- Filter D14 ~~vac~~ as above
2 VCR 1.2mg 1VP form (15)

- Hu m. 29/6/2017 E CBC

My friend



डा. बी. आर. अम्बेडकर संस्थान रोटरी कैंसर अस्पताल
Dr. B.R. Ambedkar Institute Rotary Cancer Hospital
अ.भा.आ.सं. अस्पताल / A.I.I.M.S. HOSPITAL

OPR-6

बहिरंग रोगी विभाग / Out Patient Department

अस्पताल के अन्दर धूम्रपान मना है / SMOKING PROHIBITED IN HOSPITAL PREMISES

एक/Unit Substia-clinic

IRCH No. 199891 UH10-102685943

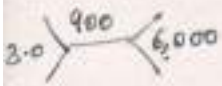
विभाग/Dept Dr. SR.

कार्डेनिक पंजीकृत सं/ O.P.D. Regn. No.

नाम/Name	लिंग/पुरु/स्त्री/एड/पुत्री F/S/W/H/D of	लिंग Sex	उम्र Age	जन्म तिथि/Date of Birth
Rishu Kumar		m	6y	

रिपोर्ट/Diagnosis Embryonal Rms of the orbit

दिनांक/Date	उपचार/Treatment
<u>18/10/2017</u> <u>Surveillance clinic</u>	<p>on VAC protocol - P/WK 75# - Now D + 9</p> <p>40 Fever - epistaxis ∴ 30 days</p> <p>0/E Pt. Conscious, oriented febrile PR-110/min RR-22/min Hct - BAED</p> <p>Received ZOPRO on 17/10/2017</p> <p>Epistaxis (+)</p> <p>Impression:- Embryonal Rms - post VAC. febrile neutropenia. ? local eye site - low / reactive bleed.</p>





डॉ. बी. आर. अम्बेडकर संस्थान रोटरी कैंसर अस्पताल
Dr. B.R. Ambedkar Institute Rotary Cancer Hospital

अ.भा.आ.सं. अस्पताल / A.I.I.M.S. HOSPITAL

बहिरंग रोगी विभाग / Out Patient Department

अस्पताल के अन्दर धूम्रपान मना है। / SMOKING PROHIBITED IN HOSPITAL PREMISES

OPR-6

CK-18293

एक/Unit Med On
विभाग/Dept. Dr. SK

IRCH No. 199891

102605943

व्यक्तिगत संकेतक सं./O.P.D. Regn. No.

नाम/Name	पिता/पुत्र/पत्नी/पुत्री/पुत्र F/S/W/H/D of	लिंग Sex	वयु Age	जन तिथि/Date of Birth
Rishu Kumar	Siyashan Paswan	Male	M	13/28 7/8

रोग/Diagnosis

Orbital RMS

(VAC) on

दिनांक/Date	उपचार/Treatment
<u>31/3/2017</u>	<p>wk=9 (Due).</p> <p>- Ij: Emet-4mg + Dexam-4mg - D₁ 3/08 14/08</p> <p>Ij: VCR- 1.2mg i.v.p - Day 1/2/15</p> <p>Ij: Actinomycin D 0.50mg i.v.p Day 1 } 31/3/2017</p> <p>Ij: Endoxan- 800mg i.v.p Day 1</p> <p>Ij: MESNA - 600mg i.v.p Day 1</p> <p><u>Post che:</u> Tab. Dexam 2mg 0-0 (रोगी के लिए) } x 3day</p> <p>Tab. J. Lenzol 15mg (रोगी के लिए) } x 3day</p> <p>Tab. Emet 2mg 0-0 x 3day</p> <p>Ij: G-CSF - 75mg - Day - 3 onwards (02/08, 3/08, 4/08, 5/08, 6/08, 7/08)</p>

CY
31/7/17
✓

अंगदान-जीवन का बहुमूल्य उपहार/ORGAN DONATION - A GIFT OF LIFE

O.R.B.O., AIIMS, 26588360, 26593444, www.orbo.org Helpline - 1060 (24 hrs service)

बाहर-से आने वाले रोगियों के लिए धर्मशाला की सुविधा उपलब्ध है/Dharamshala facility is available for outstation patients

Dr. on 10/07/2017 E CBC

vinodh
skh

823 04/07/2017:

1. Mgnox - 1.5 gm i/v BD } Today onwards
2. Amikacin - 300mg i/v OD } x 3 days

Continue G-CSF - 75mcg, s.c., OD

Syp. CROCIW (5ml=200mg) 5ml - start 42

= visit on 2/08/2017

Rapor
19/07/2017
6/8
RECEIVED

7/8

To 2/08/2017 (2d)

BBB flow down
Kish 10/07/2017
Guru

7/8/12

P - 11/07/12

Hydrate on

Amikacin

clear

if patient - Emergency Admn.

1 map/Amikacin

PLAN

1st Syp. CROCIW

Syp. Amikacin go 2st to 00 00 00 2st

- 1 OPL
- 1.5 gm Mgnox i/v BD x 7/8/12 8/8/12 9/8/12 10/8/12
- 300 mg Amikacin i/v OD x 3d 7/8/12 8/8/12 9/8/12
- 75 mg G-CSF s.c. OD 7/8/12 8/8/12

S. S. Naygi

To on 10/07/2017 E CBC



डा. बी. आर. अम्बेडकर संस्थान रोटरी कैंसर अस्पताल
Dr. B.R. Amb
अ.भा.अ
बहिर
अस्पताल के अन्दर

एम्ब/Unit D.S. Lab
विभाग/Dept. _____
नाम/Name _____

DR. B.R.A. IRCILAHIMS, NEW DELHI
IRCH No. 199891
Clinic Adult Medical Oncology Clinic
Dept. MEDICAL ONCOLOGY
General
Name RISHU KUMAR
S/O. SHYAMSHAN PASWAN
Phone No. 7260626523
Address GHURASHAN POLICE HARPOUR, BHGAR, INDIA

Reg. Date-04/05/201
Clinic No. 23982/201
UHID-10268594
Sex/Age M/6
Room 58 (Shift Morning) / Date of Birth _____

OPR-6

13/40
11/1

Rishu K.

निदान/Diagnosis C/ Rt. osteosarcoma (Non metastatic)

दिनांक/Date	उपचार/Treatment
	<u>Plan</u> <u>VAC</u> <u>wk # 23</u>
	iv EMEKIN 4mg iv
	iv DEXA 4mg iv
	↓
	iv Vincristine 0.9mg iv push D, on 7/14/12
	iv Actinomycin D 0.6mg iv push D,
	iv Cyclophosphamide 500mg iv D,
	iv Meperidine 30mg iv push D,

7/14/12
BT
U


Nov 15
Block

Parkinson

T. Emsert 8 4mg B0 Po. 0 — 0 | 3d

T. Lacta 15mg Po em

T. Dopa 2mg Po tid 

ing Cest 50mg s/c os $\times 2$ $\times 1$ $\times 0.5$  D.S. Mgr


To come on \rightarrow

ij Verclisten 0.9mg slow IV on D8 on $\frac{15}{17} \frac{17}{12}$
 $\frac{D1}{12/12/17}$ $\frac{D2}{13/12/12}$
 $\frac{D3}{14/12}$ $\frac{D4}{15/12}$ $\frac{D4}{16/12}$
 $\frac{15}{15}$ $\frac{24}{24} \frac{14}{12}$

To come on 1/1/19 r CAC, NA, UF D.S. Mgr

1/1/18 D1. mixed Doldor von Adv — ok to give.

ing to ver 0.9mg slow IV on

From 1/1/18 = CAC/CAF/CAF 



डा. बी. आर. अम्बेडकर संस्थान रोटरी कैंसर अस्पताल
Dr. B.R. Ambedkar Institute Rotary Cancer Hospital

अ.भ

Clinic: Adult Medical Oncology Clinic
Dept: MEDICAL ONCOLOGY
(General)

Clinic No. 23982/2017

IL

OPR-6



Name: RISHU KUMAR
NO: SYASIAN PALWAN
Phone No: 730020723
Address: GHERA/STATION POLICE HAUPUS, BHADEL, INDIA

UID: 102639943

MISES

Sex/Age: M/6V

Room: 58 (Shift Morning)

एक/Unit: Dr. S. Pathak
विभाग/Dept: THO

I. No.

नाम/Name

जन्म तिथि/Date of Birth

Dr. B.R. Ambedkar Institute Rotary Cancer Hospital

ICCH No. 199891

Gen. Date: 04/05/2017

Clinic: Adult Medical Oncology

Clinic No. 23982/2017

रिपोर्ट/Diagnosis

Stage 3 (metastatic) RT. Non metastatic

दिनांक/Date

8/1/18

उपचार/Treatment

VAC # 29.

By Emset 4mg IVP
By Dexam 4mg IVP

} IVP D₁ only.

By Vincristine 0.9mg IV Push D₁

By Actinomycin D 0.6mg IV Push D₁

By Cyclophosphamide 500mg IVP D₁

By MESA 400mg IV Push D₁

Plenty of oral fluids.

Post Chem.

Tab Emset 4mg P.O. $\xrightarrow{\quad}$

Tab Dexam 15mg P.O. $\xrightarrow{\quad}$

Tab Dexam 2mg P.O. $\xrightarrow{\quad}$ x 3 days.

steroid 20mg $\xrightarrow{\quad}$

By Stat Somogyi S/C x 5 days w of Day 3 of Chem

from room no: 15

D₁ (Stat) 10/1/18

D₂ 11/1/18

D₃ 12/1/18

D₄ 13/1/18

D₅ 14/1/18

VAC

CT
आधार

8/1/18
from room
no: 15

To
analyze the
level of
Coccarin
type

x 3 days
empty stomach
खाली पेट

अंगदान जीवन का बहुमूल्य उपहार/ORGAN DONATION - A GIFT OF LIFE

O.R.B.O., AIIMS, 26588360, 26593444, www.orbo.org Helpline - 1060 (24 hrs service)

बाहर से आने वाले रोगियों के लिए धर्मशाला की सुविधा उपलब्ध है/Dharamshala facility is available for outstation patients

P.T.O



J-16, Hauz Khas Enclave, Main Aurobindo Marg, New Delhi - 110016

Phone No. : 011-49515253 - (30 Lines), Email : drgulatiimaging@gmail.com

Website : www.drgulatiimaging.in

PATIENT'S NAME: RISHU KUMAR	AGE/SEX: 12/M
REF. BY: AIIMS	REG. ID: RKR2462
CONTRAST USED : YES	EXAM. DATE: 27-MAR-2017

MR imaging of ORBITS AND BRAIN was performed in sagittal, parasagittal, coronal and axial plane using dedicated synergy head coil on 3.0 Tesla MRI. SE, TSE, SPIR and FLAIR sequences were used to obtain FATSAT, T1 and T2 weighted images. Flow compensation techniques were employed to reduce flow artifacts. Diffusion weighted images were also performed. Post contrast scans reveal no significant abnormal parenchymal or meningeal enhancement. (4 ml of gadolinium was administered I.V.). No immediate contrast adverse reaction was noted.

ORBITS

The study reveals large diffusely infiltrating mass lesion in right orbit. The lesion is primarily conal and extraconal in location involving extraconal muscles and circumferentially encasing right optic nerve with resultant proptosis.

Right globe is also partially encased within mass lesion and posterior aspect of eye ball is distorted without evidence of intravitreal extension of mass lesion. The lesion is involving retrobulbar, retroseptal and retrobulbar compartment. There is intracranial extension of the lesion through the orbital apex without evidence of optic chiasma involvement.

The lesion reveals hypointense signal on T1W images and hyperintense signal on T2W images and there is intense heterogeneous post contrast enhancement of the lesion seen.

Right side lamina papyracea is intact with normal signal intensity of lateral orbital wall.

Left globe appears normal. There is no proptosis on left side. Left retro bulbar compartment is normal. Left extra ocular muscles appear normal. The left optic nerve appears normal in integrity and signal intensity.

BRAIN

The brain parenchyma appears normal in the supratentorial compartment. There is no mass effect or midline shift. There is no fresh infarct on DW images.

Post contrast scans reveal no significant abnormal parenchymal or meningeal enhancement.

Brain stem and bilateral cerebellar hemispheres appear normal.

Cont...2



J-16, Hauz Khas Enclave, Main Aurobindo Marg, New Delhi - 110016
Phone No. : 011-49515253 - (30 Lines), Email : drgulatimaging@gmail.com
Website : www.drgulatimaging.in

(2)

PATIENT'S NAME: RISHU KUMAR	AGE/SEX: 12/M
REF. BY: A I I M S	REG. ID: RKR2462
CONTRAST USED : YES	EXAM. DATE: 27-MAR-2017

Bilateral CP angles are normal. No CP angle mass seen. Bilateral 7th & 8th nerve complexes are normal.

The sella turcica is normal in size. Suprasellar and parasellar regions appear normal.

The lateral, third and fourth ventricles appear normal. Cortical sulci and bilateral sylvian fissures are normal.

CSF shows normal signal. There is no compression at the CV junction.

Note is made of right mastoiditis.

IMPRESSION: CEMRI findings reveal right sided intensely enhancing extra-orbital mass lesion involving conal and extraconal, pre / parasellar and retrobulbar compartment with resultant proptosis. There is involvement of extraocular muscles encasing the right optic nerve. There is intracranial extension of the lesion through the orbital apex without evidence of optic chiasma involvement. Findings likely represent rhabdomyosarcoma. Left orbit is unremarkable. MRI Brain within normal limits. *Please correlate clinically.*

DR. PARVEEN GULATI, M.D
DMC 333B


DR. NIDHI GOYAL
DMRD, DNS, FRCR
Sr. Consultant (DMC 27157)

RADIOLOGY UNIT

Dr. B. R. Ambedkar Institute Rotary Cancer Hospital
All India Institute of Medical Sciences, New Delhi-110029

Patient Name: MrRishu Kumar	Age/Gender: 6 Years and 5 Months / M
Patient UHID : 102685943	IRCH No : 199891
Accession No : 510925	Location : MD DPD
Date of Examination : 12-SEP-2017 10:16 AM	

CECT of Head, Neck, Chest.

Clinical background: RMS right orbit post chemo status.

Head and orbits-

A large heterogeneously enhancing mass lesion with preseptal / postseptal component seen (44x 43 mm) in right orbit involving orbital contents including eye globe, muscles and optic nerve with bony remodelling.No bony erosion/destruction s seen. No cavernous sinus or intracranial extension is seen

Posterior fossa: Normal. Cerebral parenchyma: Normal.
Ventricles: Normal. Subarachnoid spaces: Normal.
Basal ganglia and thalami: Normal.

Neck:

Sinonasal cavities: Normal.
Pharynx/ larynx: Normal.
Neck spaces: No lymph node enlargement.

Chest and upper abdomen

Mediastinum: Normal, No lymph node enlargement.
Both lungs: Normal, No focal lesion.
Serosal Spaces: No pleural or pericardial effusion.

Liver/ gall bladder: Normal.
Spleen, pancreas,
both kidneys: Normal.
Retroperitoneum/ vessels: No significant lymph node enlargement.

Comparison: with previous CT dated on 18/5/2017 size of mass is decreased (approx 50%)

Impression: Post chemo c/o of RMS- residual right orbital mass - partial response.

Radiologist: Dr. Richa Yadav (SR) / Dr. Sanjay Thulkar



प्रयोगशाला कायचिकित्सा विभाग
DEPARTMENT OF LABORATORY MEDICINE
नैदानिक रसायनिक
CLINICAL CHEMISTRY

अखिल भारतीय आयुर्विज्ञान संस्थान, अंसारी नगर, नई दिल्ली-110029
All India Institute of Medical Sciences, Ansari Nagar, New Delhi-110029
रक्त रसायन / BLOOD CHEMISTRY

UHD: 102685943 Sample No: CH-2012170606
Name: Mr RISHU KUMAR, Male Lab Ref No: 771
Ward Name: Verification Time: 20/12/2017 06:02 pm

Report

Test Name	Result	Comment	Normal Range
UREA	10 mg/dL		10.00-40.00
CREATININE	0.2 mg/dL		0.50-1.00
CALCIUM	8.5 mg/dL		8.50-10.50
PHOSPHATE	4.3 mg/dL		2.50-4.50
URIC ACID	2.1 mg%		• 3.5 - 7 mg/dL
SODIUM	140 mEq/L		135.00-145.00
POTASSIUM	4.6 mEq/L		3.50-5.00
BILIRUBIN TOTAL	0.2 mg/dL		0.20-1.20
TOTAL PROTEIN	6.6 g/dL		6.00-8.00
ALBUMIN	4.2 g/dL		3.50-5.00
GLOBULIN	2.4 g/dL		2.00-3.50
SGOT (AST)	47 U/L		5.00-40.00
SGPT (ALT)	15 U/L		5.00-45.00
ALK PHOS (ALP)	605 IU/L		• 240 - 840 IU/L

Over All Comment :

Authorised Signatory
Dr. Sudip Kumar Datta

Verified By
sudhaman



प्रयोगशाला कार्यचिकित्सा विभाग
DEPARTMENT OF LABORATORY MEDICINE
बैज्ञानिक रसायनिक
CLINICAL CHEMISTRY

अखिल भारतीय आयुर्विज्ञान संस्थान, अंसारी नगर, नई दिल्ली-110029
All India Institute of Medical Sciences, Ansari Nagar, New Delhi-110029
रक्त रसायन | BLOOD CHEMISTRY

UHID: 102685943
Name: Mr RISHU KUMAR
Ward Name:

Sample No: CH-2501180739
Lab Ref No: 827
Verification Time: 25/01/2018 07:35 pm

Report

Test Name	Result	Comment	Normal Range
UREA	16 mg/dL		10.00-40.00
CREATININE	0.2 mg/dL		0.50-1.00
CALCIUM	8.9 mg/dL		8.50-10.50
PHOSPHATE	4.9 mg/dL		2.50-4.50
URIC ACID	3.0 mg%		• 3.5 - 7 mg/dL
SODIUM	146 mEq/L		135.00-145.00
POTASSIUM	4.0 mEq/L		3.50-5.00
TOTAL PROTEIN	6.2 g/dL		6.00-8.00
ALBUMIN	4.5 g/dL		3.50-5.00
GLOBULIN	1.7 g/dL		2.00-3.50
SGOT (AST)	31 U/L		5.00-40.00
SGPT (ALT)	32 U/L		5.00-45.00
ALK PHOS (ALP)	648 IU/L		• 240 - 840 IU/L
BILIRUBIN TOTAL	0.3 mg/dL		0.20-1.20

Overall Comment :

+ DURGA MEDICOSE +

KIOSK NO. 55, SAFDARJUNG HOSPITAL, GATE NO. 2, NEW DELHI-29, Ph.: 011-26168992



GST INVOICE

Bill No. : 160608
 Patient : RISHU KUMAR
 Address :
 Prescribed by : AIIMS

Date : 03/11/17
 Time : 03:58 PM

QTY.	PARTICULARS	HSN	GST%	BATCH	EXPIRY	AMOUNT
1	ACIVIR-CREAM.	30049099	12.0	07199	06/20	54.50

.D.L.NO.:S(1991) 15R

Taxable 5%	0.00	CGST 2.5%	0.00	SGST 2.5%	0.00
Taxable 12%	48.66	CGST 6%	2.92	SGST 6%	2.92
Taxable 18%	0.00	CGST 9%	0.00	SGST 9%	0.00
Taxable 28%	0.00	CGST 14%	0.00	SGST 14%	0.00
Taxfree %	0.00	CGST 0%		SGST 0%	
CGST Total	2.92			MRP TOTAL	54.50
SGST Total	2.92			DIS. AMT.	
oper:- SATISH KUMAR				PAID AMT.	54.00

BHAVESH WISHRA,
 GSTIN : 07ABPPK4453M1Z4 D.L.No.: S (1991) 13R

Note : Cutting strips & fridge items (without ice) will not be returned
 Medicine will not return after Ten Days

FOR : DURGA MEDICOSE

INDIAN PAPERS Pvt. Ltd. ESTD 1978

Dept No.



CASH RECEIPT
ALL INDIA INSTITUTE OF MEDICAL SCIENCES
C.N. Centre, Ansari Nagar, New Delhi-110029

Phones } 26594235
26593824

ACCOUNTS-5/15534/2017/14
Receipt No. CNC Receipts
Received For: MR. KUMAR, Age - 45 Yrs 1 Moon 28 Days
OPD/ MRD/ (OPD)
ON ACCOUNT OF

General Dated :
Patient Type :
Room No. :

Sl No.	Service Name	Quantity	Rate	Net Amount
1	OPD (CNC) - 1200/-	1	25	25
Printed on 17 May 2017 10:57:42 AM				



शरीरमाद्यं खलु धर्मसाधनम्

Cash
25.0

Payment Mode: Rupees Twenty Five Only
INR (Rs.) :
Rs. in Words

MR. NEERAJ KHANNA CNC

+ AMBEY MEDICINE CORNER +

37-A/S, GATE NO. 2, SAFDARJUNG HOSPITAL, OPP. AIIMS MAIN GATE, NEW DELHI-29, Ph.: 26193664

Bill No. : 95111
 Patient : RISHU KUMAR
 Address :
 Prescribed by : AIIMS

GST INVOICE

Date : 10/10/17
 Time : 09:05 AM

IP

BIDDAN PAPER PVT. LTD. DELHI, INDIA

QTY.	PARTICULARS	HSN	GST%	BATCH	EXPIRY	AMOUNT
10	ONDETAS 4MG TAB	30049035	12.0	T-1209	09/18	55.0

SERVICE
24 Hrs.



ALL DAYS
OPEN

Taxable 5%	0.00	CGST 2.5%	0.00	SGST 2.5%	0.00
Taxable 12%	49.11	CGST 6%	2.95	SGST 6%	2.95
Taxable 18%	0.00	CGST 9%	0.00	SGST 9%	0.00
Taxable 28%	0.00	CGST 14%	0.00	SGST 14%	0.00
Taxfree %	0.00	CGST 0%		SGST 0%	
CGST Total	2.95			MRP TOTAL	55.00
SGST Total	2.95			DIS. AMT.	
oper:- RAN PRKASH				PAID AMT.	55.00

GSTIN : 07AGHPB6470A1ZV D.L. No. : S(1117)13R,

Note : Cutting strips & fridge items (without ice) will not be returned
 Medicine will not return after Ten Days

FOR : AMBEY MEDICINE CORNER

J K M

RETAIL INVOICE / CASH MEMO

+ AMBEY MEDICINE CORNER +

37-A/5, GATE NO. 2, SAFDARJUNG HOSPITAL, OPR, AIIMS MAIN GATE
NEW DELHI-110 029. PHONE : 26193604

CREDIT CARD
ACCEPTED

D.L. No. : S(1117)13R,

TIN : 07140282762

ALL DAYS
OPEN

* If you see first any inadvertent error in the price charged
Please bring this Retail Invoice for refund of difference.

QTY.	PARTICULARS	BATCH NO.	EXP. DT.	VAT	AMOUNT
------	-------------	-----------	----------	-----	--------



BILL NO. :	DATE :	Total
PATIENT NAME :		VAT @ 5%
ADDRESS :		VAT @ 12.5%
Pres. by Dr :		VAT Free
	Sign.	Grand Total

1. No Return, No Exchange
2. All Disputes are subject to Delhi Jurisdiction only

For : AMBEY MEDICINE CORNER

IP

www.ambeymedicinecorner.com

1301

सेवा में:-

UTTHAN TRUST

विषय:- मेरा बड़ा रिशु कुमार के इलाज के सम्बन्ध में मेरा नाम सिहासन पासवन गांव दोरासन पुलिस हस्तपुर बिहार उत्तर प्रदेश

मेरा बच्चा जिसका नाम रिशु कुमार जिसका उम्र 6 साल है। जो इस समय नेत्र कैंसर से पीड़ित है। जिसका इलाज सर्स अस्पताल में कैंसर के डॉक्टर समीर के द्वारा इलाज किया जा रहा है। इलाज में काफी खर्चा हुआ है। जबकि मैं एक भक्त आदमी हूँ। जो शैल भावदूरी करके अपना घर चला रहा हूँ। और अपने बच्चे का इलाज अच्छे से कराने में सक्षम नहीं हूँ। और अपने बच्चे को बचाने के लिए मैं अभिषेक तिवारी जी व UTTHAN TRUST से विनम्र करती हूँ कि वो हमें मदद करें। इसके लिए मैं सदा UTTHAN TRUST का आभारी रहूँगा।

नाम:- सिहासन पासवन

DATE - 31-01-2018



Accepted
UTTHAN TRUST
NEW DELHI