

HELP ME
TO FIGHT
WITH
CANCER



डा. बी. आर. अम्बेडकर संस्थान रोटरी कैंसर अस्पताल
Dr. B.R. Ambedkar Institute Rotary Cancer Hospital

DR. B.R.A. IRCH, AIIMS, NEW DELHI

A.I.I.M.S. HOSPITAL

OPR-6


IRCH No. 197560

Reg. Date-02/03/2017

Clinic Paediatric Medical Oncology Clinic

Clinic No. 4516/2017

Deptt. MEDICAL ONCOLOGY
General



Name BAIHAR ASULAM

ID-102570210

S/O- ABULKASAM

Sex/Age M/8Y

Phone No. 9551263491

Room 5 (Shift Morning)

Address KHUTHKIJUTHI SHANTI VILLAGE DIST. DIBRU, ASSAM,
INDIA

Patient Department
PROHIBITED IN HOSPITAL PREMISES

य०रो०वि० पंजीकृत सं०/O.P.D. Regn. No.

लिंग Sex	आयु Age	जन्म तिथि/Date of Birth

DR. B.R.A. IRCH, AIIMS, NEW DELHI

निदान/Diagnosis

RB

दिनांक/Date

13/01/17

उपचार/Treatment

Ref to RT-OPD,

DR Anit
मं० शुक
शुके 7 वजे

[Handwritten signature]

अंगदान-जीवन का बहुमूल्य उपहार/ORGAN DONATION - A GIFT OF LIFE

O.R.B.O., AIIMS, 26588360, 26593444, www.orbo.org Helpline - 1060 (24 hrs service)

बाहर-से आने वाले रोगियों के लिए धर्मशाला की सुविधा उपलब्ध है/Dharamshala facility is available for outstation patients



डा. बी. आर. अम्बेडकर संस्थान रोटरी कैंसर अस्पताल
 Dr. B.R. Ambedkar Sansthan Rotary Cancer Hospital

DR. B.R.A. IRCIAHMS, NEW DELHI

ary Cancer Hospital
M.S. HOSPITAL

OPR-6

IRCH No. 197560 Reg. Date-02/03/2017
 Clinic Paediatric Medical Oncology Clinic Clinic No. 4516/2017
 Deptt. MEDICAL ONCOLOGY
 General

nt Department
 SITED IN HOSPITAL PREMISES

एकक/Ur
 विभाग/De

Name BAHARASULAM UIHD-102570210
 S/O: ABULKASAM Sex/Age M/8Y
 Phone No. 9531263491 Room 5 (Shift Morning)
 Address KHUTHKHUTHI SHANTI VILLAGE DIST. DIBRU, ASSAM,
 INDIA

to पंजीकृत सं०/O.P.D. Regn. No.

आयु
 Age

जन्म तिथि/Date of Birth

निदान/ Diagnosis

दिनांक/Date

उपचार/ Treatment

29/6/17

To meet Dr. Rachna Meel
 for Pri. Gx - RPE
 Sameer Bakshi

अंगदान-जीवन का बहुमूल्य उपहार/ORGAN DONATION - A GIFT OF LIFE

O.R.B.O., AIIMS, 26588360, 26593444, www.orbo.org Helpline - 1060 (24 hrs service)

बाहर से आने वाले रोगियों के लिए धर्मशाला की सुविधा उपलब्ध है/Dharamshala facility is available for outstation patients



डा. बी. आर. अम्बेडकर संस्थान रोटरी कैंसर अस्पताल
Dr. B.R. Ambedkar Institute Rotary Cancer Hospital

अ.भा.आ.सं. अस्पताल / A.I.I.M.S. HOSPITAL

बहिरंग रोगी विभाग / Out Patient Department

अस्पताल के अन्दर घूमपान मना है। / SMOKING PROHIBITED IN HOSPITAL PREMISES

OPR-6

IRCH No. 197560

ब०रो०दि० पंजीकृत सं० / O.P.D. Regn. No. RTA-97996

एक/Unit
विभाग/Dept.

नाम/Name	पिता/पुत्र/पत्नी/पति/पुत्री F/S/W/H/D of	लिंग Sex	आयु Age	जन्म तिथि/Date of Birth
Bahar Asulam Bahar Alam		M	4	

निदान/Diagnosis

R.M

दिनांक/Date	उपचार/Treatment
14/9/17	Ref to R.P. Center - for eye evaluation (Dr. Rachna Meel)
6/17 17/11	
5/70 14/11	
14/11/17	Kindly register & RT-II Counter no 516 Room no 5 Sub SRAT
25/11/17 - 12 noon	
29/11/17 - 12 noon	
30/11/17 - 12 pm	
31/11/17 - 12 pm	
1/12/17 - 12 pm	

अंगदान-जीवन का बहुमूल्य उपहार / ORGAN DONATION - A GIFT OF LIFE

O.R.B.O., AIIMS, 26588360, 26593444, www.orbo.org Helpline - 1060 (24 hrs service)

बाहर से आने वाले रोगियों के लिए धर्मशाला की सुविधा उपलब्ध है / Dharamshala facility is available for outstation patients

14/10/17

ds/B Dr. S. Pathy

Case to be discussed in tumor board tomorrow

Adm:

① Review to post op HPR → Thu; Room no. 5
→ Fri; Room no. 6; 8:30 am Counter ⑤/⑥



17/11/17 To see Dr. Rachna Meel / Dr. Lomi

P. provide a brief summary + HPE report to decide for Adjuvant RT

AOC at 12 noon
12:30 pm

To Lomi
17/11/17

19/12/17 - RA give IRCH file

Tu
ERRT

20/12/17

DART 20# [] Ra. 28

To say 750g for RT changes

Please exempt RT changes.
Ritesh Kumar.

ERRT

डॉ. रितेश कुमार, एम डी / Dr. RITESH KUMAR, MD
सहायक अध्यापक / Assistant Professor
विश्वविद्यालय / Department of Radiotherapy
एन सी ई सी, एन सी ई सी, एन सी ई सी / Dr. B. R. Ch. I. R. Ch. A. I. I. M. &
असानी नगर, जय सिंह-29 / Ansan Nagar, New Delhi-29

①
②



डा. बी. आर. अम्बेडकर संस्थान रोटरी कैंसर अस्पताल

Rotary Cancer Hospital

A.I.I.M.S. HOSPITAL


Patient Department

PROHIBITED IN HOSPITAL PREMISES

4/7/1
NIC
OPR-6

DR. B.R.A. IRCH, AIIMS, NEW DELHI

UHID: 102570210



IRCH No. 197560

General

Name BAHAR ASULAM

S/O- ABULKASAM

Sex/Age M/8Y

Phone No. 9531263491

Address KHUTHIKHUTHI SHANTI VILLAGE DIST. DIBRU, ASSAM, INDIA

ब०रो०वि० पंजीकृत सं०/O.P.D. Regn. No.

लिंग Sex	आयु Age	जन्म तिथि/Date of Birth

निदान/Diagnosis

RB (RE)

दिनांक/Date	उपचार/Treatment
13/11	file NA
24/9	CEV (C# 36)
13/11	Eriect 4j IV } (D1)
4/10	Dexa 4j IV }
	VCR 1.3g IV }
	Carboplatin 475g ~ 500mg 57.0 IV aa 2 kan (D1)
18/10	Etoposide 250g ~ 500mg 57.0 IV aa 2 kan (D1)
20/10/12	Post-Chemo, T Eriect 4j TO } T Dexa 4j BO } 5 dy T Postoy 20g BO }

अंगदान-जीवन का बहुमूल्य उपहार/ORGAN DONATION - A GIFT OF LIFE
O.R.B.O., AIIMS, 26588360, 26593444, www.orbo.org Helpline - 1060 (24 hrs service)
बाहर-से आने वाले रोगियों के लिए धर्मशाला की सुविधा उपलब्ध है/Dharamshala facility is available for outstation patients

19/10 CBQBC

3/10/17

fever (2) days
URI symptoms (+)

3/10/2017

Adi: (CBC) (w)

o - o - o 2ab. Augmentin 375mg TDS
1cpr. Grillinclax 2tq BD (5) days
(v) (v)

from 4/10 CBC reports

Room (13) 10am

4.10.2017

file mining

CBC/labs (w)

From 12/10/17
to Section

completed vac 5 #

see
2/10/17
JR

Refer to RPC for EUA dates

proceed with cycle # 6 as written overleaf

~~See~~

from 01/11/2017 with CBC + labs

to make duplicate file

11/11/17 Admitted in RPC for EUA
to ~~of~~ ~~status~~
13/11/17 make



डा. बी. आर. अम्बेडकर संस्थान रोटरी कैंसर अस्पताल
Dr. B.R. Ambedkar Institute Rotary Cancer Hospital

शरीरवाचं सतुप्रसामानम्

अस्पताल के

DR. B.R.A. IRCHLAHIMS, NEW DELHI

OPR-6

एकक/Unit

DSB

विभाग/Dept.

नाम/Name

CH No. 197560

Reg. Date-02/03/2017

Paediatric Medical Oncology Clinic

Clinic No. 4516/2017

pt. MEDICAL ONCOLOGY



No.

General

नाम तिथि/Date of Birth

Name BAHAR ASULAM

UHID-102570210

O- ABULKASAM

Sex/Age M/8Y

Phone No. 9531263491

Room 5 (Shift Morning)

Address KHUTHKHUTHI SHANTI VILLAGE DIST. DIBRU, ASSAM, INDIA

निदान/Diagnosis

RB

दिनांक/Date

उपचार/Treatment

80/12/17

Day +12 of VEE

wt = 20kg

• Fever undocumented

• Afebrile in OPD.

• Hemodynamically stable

• Contractions.

PHARMACY
(1) MEDICINE RECEIVED
DATE
SIGN

Plan

Tab Augmentin 625mg 1/2 Tablet TDS ~~OD~~ X 5 days

Tab Crocin 500mg 1/2 Tablet Soft fever

Sp 10ml HS for Contractions (Free)

अंगदान-जीवन का बहुमूल्य उपहार/ORGAN DONATION - A GIFT OF LIFE

O.R.B.O., AIIMS, 26588360, 26593444, www.orbo.org Helpline - 1060 (24 hrs service)

बाहर से आने वाले रोगियों के लिए धर्मशाला की सुविधा उपलब्ध है/Dharamshala facility is available for outstation patients

Plan in OPD on Given Date



डा. बी. आर. अम्बेडकर संस्थान रोटरी कैंसर अस्पताल
Dr. B.R. Ambedkar Institute Rotary Cancer Hospital

आर. बी. आर. अम्बेडकर संस्थान / A.I.I.M.S. HOSPITAL

OPR-6

DR. B.R.A. IRCLAIMS, NEW DELHI
IRCI No: 197560 Reg. Date: 02/03/2017
Clinic: Paediatric Medical Oncology Clinic Clinic No: 4516/2017
Deptt: MEDICAL ONCOLOGY
Genepn
Name: BAHAR ASULAM UHID-102570210
S/O: ABULKASAM Sex/Age: M/8Y
Phone No. 9531263491 Room 5 (Shift: Morning)
Address: KHUTHKHUTHI SHANTI VILLAGE DIST. DIBRU, ASSAM, INDIA

Patient Department
PROHIBITED IN HOSPITAL PREMISES

ब०रो०वि० पंजीकृत सं०/O.P.D. Regn. No. _____

लिंग Sex	आयु Age	जन्म तिथि/Date of Birth
-------------	------------	-------------------------

BR-26
11/11/17

निदान/Diagnosis

RD

दिनांक/Date	उपचार/Treatment
13/11/17	C#7
2nd Day	1. Inj. VCR 1.3 mg IVP 2. Inj. Carboplatin 600mg in 1057.3 3. Inj. VP-16 250 mg in 1057.3 4. Inj. Zofen 4mg IVP 5. Inj. Dexam 4mg IVP
Generic PHARMACY	6. Zofen 4mg 7. Sucraman 4mg 8. Fu with CBC LFT/RFT on 11/12/17
	Lupa-Z BOS 5ml Sameran Bakshi

NAME: 13/11/17
DATE:
SIGN:

R.C. ISSUE

अंगदान-जीवन का बहुमूल्य उपहार/ORGAN DONATION - A GIFT OF LIFE

O.R.B.O., AIIMS, 26588360, 26593444, www.orbo.org Helpline - 1060 (24 hrs service)
वाहर से आने वाले रोगियों के लिए धर्मशाला की सुविधा उपलब्ध है/Dharamshala facility is available for outstation patients

21.11.17

Chlorhexidine gargles Q6hrly ○○○○

Steam inhalation Q6hrly ○○○○ (भाप)

Syr. Looz 10ml Hs OD (for constipation)
2. चम्मच रोज दो बार से पहले

Tab. CROCIN 500mg (1/2) tab SOS

digital thermometer.



* fever precautions


11/12/17

C#8

2nd floor day care

1. Apt. above cycle

2. Fo with CBC + LFT/RFT on 4/1/18
sample of sputum



4/1/18

Post C#8 VEC.

• Fvd 10.1 > 1320 / 490 L 52000

• Fever & cough

Amika NA

Admic

- Sy. Magna 2gm 10 80
- Sy. Amikacin 30mg 1000
- Sy. G-CSF 150mg Hc 500.

x 5 day

Room no - 15

-> x Ray chest

-> Review on 8/1/18 CBC/Ser

D1 4/1/18

D2 5/1/18

D3 10/1/18

D4 14/1/18

D5 19/1/18

(only m)

(Amika NA)

(Amika NA)

(Amika NA)

(Amika NA)

(Amika NA)

Dr. B. R. AMBEDKAR INSTITUTE ROTARY CANCER
ALL INDIA INSTITUTE OF MEDICAL SCIENCES NEW DELHI

DISCHARGE SLIP

197560	IRCH NO	197560	Ward	DAYCARE	
Name	DR. SAMEER BAKHSHI	Age	8	Sex	Male
Name	Mr BAHAR ASULAM				
Admission For	CHEMOTHERAPY	Admission Date	19/12/2017	Discharged Date	19/12/2017

Diagnosis

Chemo. Protocol: VEC in /m2 D1,D2 q 4 wkly

Cycle/Day: C8

Drugs Administered

PREMEDICATION GIVEN

Inj Ondansetron 4 mg IVP

Inj Dexamethasone 4 mg IVP

CHEMOTHERAPY/IMMUNOTHERAPY GIVEN

Drug Name	Final Dose	Unit	Soln.	Infusion
Inj Vincristine D1	1.3mg	IVP		
Inj Etoposide D1,D2	250mg	250 m	5%D	1 hr
Inj Carboplatin D1	600mg	500 m	5%D	1 hr

Advice

Re-appointment in on 19/12/2017

Signature of Physician
DR ARUN GARG

1.45pm: Pt had anaphylactic reaction with carboplatin. Lft c/o itching & redness over the body. Informed Dr. Arun. Gg = Hydrocortisone & inj. Avil IVP given as per order. Infusion stopped for sometime & restarted slowly by Dr. Sopam.

Jor

14/11/18

बी. आर. अम्बेडकर संस्थान रोटरी कैंसर अस्पताल B.R. Ambedkar Institute Rotary Cancer Hospital

IRCH No. 197560 Reg. Date-02/03/2017
Clinic Paediatric Medical Oncology Clinic Clinic No. 4516/2017
Deptt. MEDICAL ONCOLOGY General
Name BAHAR ASULAM UHID-102570210
S/O- ABULKASAM Sex/Age M/8Y
Phone No. 9531263491 Room 5 (Shift Morning)
Address KHUTHKHUTHI SHANTI VILLAGE DIST. DIBRU, ASSAM, INDIA

AL OPR-
EMISES
n. No.
नम तिथि/Date of Birth

अस्पताल
Unit First
Dept. Medico
नाम/Name

DR. B.R.A. IRCH, AIIMS, NEW DELHI

UHID: 102570210

निदान/Diagnosis

RR stage III

दिनांक/Date

उपचार/Treatment

8/1/18

Chemo → ENUDEAKEN → chemo
C# 9 VEC due on 16/01/2018.
R7 dialysis fr 24/01/18

94 week

Dear Dr. Ranvijay for Uraj

Plan C# 9 VEC wref 16/01/18 f check up

Please postpone date to 16/1/18
taken pnc 3 weekly date

- En. OXANDROLONE 4mg IV
- En. DEXAMETHASONE 4mg IV
- En. VCR 1.3 mg IV
- En. VT-16 (250) mg en 50ml ST. No/10/2018
- En. CARBOPLASTIN (600) mg en 50ml ST. No/10/16.

POST-chemo

Tab. Emeret 4mg TDS 0-0-0
Tab. Pava 4mg BD 0-0-0

1mg
16/1/18
AL

08/01/18

अंगदान-जीवन का बहुमूल्य उपहार/ORGAN DONATION - A GIFT OF LIFE
O.R.B.O., AIIMS, 26588360, 26593444, www.orbo.org Helpline - 1060 (24 hrs service)
बाहर-से आने वाले रोगियों के लिए धर्मशाला की सुविधा उपलब्ध है/Dharamshala facility is available for outstation patients

(P.7.0)

ब० रो० वि० कार्ड



अनुभाग व दिन
Section and Day I
सोमवार व बुहस्पतिवार
Monday & Thursday

कमरा नंबर
Cabin No.

डा० राजेन्द्र प्रसाद
अ०भा०आयु०सं०
Dr. Rajendra Prasad
A.I.I.M.S., New
यु एच आई
UHID No.

Dr. Rajendra Prasad Centre for Ophthalmic Sciences
UHID: 102256554
Dept. No.: 20160050123513
MD BAHARUL ISLAM 6Y/M
S/O: ABUL KASIM

Date: 29/09/2016
General ₹10
RPC OPD-Dr. ROHAN
CHAWLA
Unit-I
Room No.: 1
MON, THU

Address: DIST. KARBIANGLONG, ASSAM, INDIA
Mobile: 8471804981

रोगी
Name of the

पता
Address

दिनांक DATE	निदान DIAGNOSIS
	उपचार Treatment
	<p>NOPL Unaided 6/6</p> <p>40 days redness</p> <p>water 4x/day</p> <p>pt brown outside</p> <p>pt seen outside - (P) 21 Retinoblastoma</p> <p>21 coats dx</p> <p>ct 11/11/15 - retinoblastoma</p>

कृपया इस कार्ड को सुरक्षित रखें तथा अस्पताल में दिखाने के समय हर वक्त साथ लायें।
Kindly keep this Card safely and bring it on your follow-up visits.

१. धूपपान निषेध २. कूड़ा कर्कट केवल कूड़ेदान में ही डालें ३. थूकिये नहीं

DR. RAJENDRA PRASAD CENTRE FOR OPHTHALMIC SCIENCES

UHID: 102570210
 Dept. No.: 20170050017235
 BAHAR ASULAM
 S/O: ABULKASAM

Date: 10/11/2017
 General
 RPC OPD-Dr. Rachna Meel
 Unit-V TUE, FRI
 Room No.: 33

Address: KHUTHKHUTHI SHANTI VILLAGE DIST DIBRU, ASSAM, INDIA
 Mobile: 9531263491



अनुभाग व दिन
 ation and Day
 वार व शुक्रवार
 sday & Friday

कमरा नंबर
 Cabin No.

V

2

का एकक
 arma's Unit

रोगी का नाम
 Name of the patient

S/D/W

Sex

आयु
 Age

पता
 Address

दिनांक
 DATE

निदान
 DIAGNOSIS

उपचार Treatment

10 NOV 2017

(R) emulated for Rb (Post MAC)
 for ExhoOcrb.

17-1453 /

(R) / G Refresh tear 4td
 G Moxrup 4td

Caplex Ointment on sutures

Review
 a. G was
 Rachna

कृपया इस कार्ड को सुरक्षित रखें तथा अस्पताल में दिखाने के समय हर वक्त साथ लायें।
 Kindly keep this Card safely and bring it on your follow-up visits.

१. धूम्रपान निषेध २. कूड़ा कर्कट केवल कूड़ेदान में ही डालें ३. थूकिये नहीं

29/5

ब० रो० वि० कार्ड O.P.D. Card



अनुभाग व दिन
Section and Day
मंगलवार व शुक्रवार
Tuesday & Friday

कमरा नंबर
Cabin No.

डा० राजेन्द्र प्रसाद नेत्र विज्ञान केन्द्र,
अ० भा० आय० सं० नई दिल्ली - ११००२९

Dr. R. RAJENDRA PRASAD CENTRE FOR OPHTHALMIC SCIENCES

यु एच
UHID

UHID: 102570210
Dept. No.: 20170050017235
BAHAR ASULAM
S/O: ABULKASAM

Date: 05/05/2017

RPC OPD-Dr. Rachna Meel
Unit-V TUE, FRI
Room No.: 33

Address: KHUTHKHUTHI SHANTI VILLAGE DIST. DIBRU, ASSAM, INDIA
Mobile: 9531263491



दि
DATE
DIAGNOSIS
Retinoplastomy

15 MAY 2017
Soumit Watter
(LFP)
6/8/114
MSSD

उपचार Treatment
(R) Suspected Ab

*has received 2 cycles of chemotherapy
last cycle on 3/5/2017*

The tumor has shrunken by 50%.

clo bleedly since today morning

*Adv CBC (including Platelet counts)
in Emg.*

*To show
in ext OPD
in afternoon
report*

*Adv Pad + Patch
@ (14)
Patches - complex treatment*

कृपया इस कार्ड को सुरक्षित रखें तथा अस्पताल में दिखाने के समय हर वक्त साथ लायें।
Kindly keep this Card safely and bring it on your follow-up visits.

१. धूम्रपान निषेध २. कूड़ा कर्कट केवल कूड़ेदान में ही डालें ३. थूकिये नहीं

(Signature)

ब० रो० वि० कार्ड
O.P.D. Card

डा० राजेन्द्र प्रसाद नेत्र विज्ञान केन्द्र,
अ० भा० आयु० सं०, नई दिल्ली - ११००२९
Dr. Rajendra Prasad Centre for Ophthalmic Sciences
A.I.I.M.S., New Delhi-110029



वेद अमृत्य उपहार है जो आप ही दे सकते हैं

अनुभाग व दिन
Section and Day
मंगलवार व शुक्रवार
Tuesday & Friday

V

कमरा नंबर
Cabin No.

यु एच आई डी संख्या
UHID No.

आचार्य प्रदीप शर्मा का एकक
Prof. Pradeep Sharma's Unit

रोगी का नाम Name of the patient	पुत्र/पुत्री/पत्नी S/D/W	लिंग Sex	आयु Age	पता Address
Baha Aslam				

दिनांक DATE	निदान DIAGNOSIS
----------------	--------------------

दिनांक DATE	निदान DIAGNOSIS	उपचार Treatment
17/11/2017	Chemical Summary	
①	Presented Stage III Rb (R) with Orbital mass noted on MRI (large) - in March 2017	
②	Rptd EUA of (L) - shows it is wnl	Neoadjuvant
	→ Enucleated after chemo (6 cycles)	
③	HPE - shows no extraocular tumor cells (17-453) only few viable cells in vitr cavity.	
	Rpd for RT in view of stage III Rtinoblastoma	
		Doelma

कृपया इस कार्ड को सुरक्षित रखें तथा अस्पताल में दिखाने के समय हर वक्त साथ लायें।
Kindly keep this Card safely and bring it on your follow-up visits.

१. धूम्रपान निषेध २. कूड़ा कर्कट केवल कूड़ेदान में ही डालें ३. थूकिये नहीं

ब० रो० वि० कार्ड
O.P.D. Card



अनुभाग व दिन
Section and Day
शुक्रवार
Friday

कमरा नंबर
Cabin No.

डा० राजे
अ० भा०
Dr. Rajen
A.I.I.M.S.
यु एच आ
UHID N.

DR. RAJENDRA PRASAD CENTRE FOR OPHTHALMIC SCIENCES

UHID: 102570210
Date: 14/03/2017
General

Dept. No.: 20170050017235
RPC OPD-Dr. Rachna
Meel

BAHAR ASULAM SY/M
Unit-V TUE, FRI

S/O: ABULKASAM
Room No.: 33

Address: KHUTEKHUTHI SHANTI VILLAGE DIST. DIBRU, ASSAM, INDIA
Mobile: 9531263491

15

नाम

पता
Address

दिनांक
DATE

निदान
DIAGNOSIS

उपचार Treatment

14 MAR 2017

flu (G) old of clinic.
15/3/17 2pm for Dr. Rachna opm
[optd incursion biopsy]

5/4/17

qs. in RPC Emergency
clo span eye

del
- Dr. Vannab
- Dr. Rantre
pump 2 IM stat.
pump 1M stat.

flu touch in OPD (units) R

कृपया इस कार्ड को सुरक्षित रखें तथा अस्पताल में दिखाने के समय हर वक्त साथ लायें।
Kindly keep this Card safely and bring it on your follow-up visits.

१. धूपपान निषेध २. कूड़ा कर्कट केवल कूड़ेदान में ही डालें ३. थूकिये नहीं

दिनांक - Date

उपचार- Treatment

5/5/17

cts in casualty

inj Voveron / ampule stat L.M.
cto severe pain

7 MAR 2017

19/4/2017

Proptosis has increased ~~after~~
has received 1 cycle of chemo
To review after 2nd cycle of
chemo for planning
execution

Tue / Fri (33)

Arora

22/4/17 cts by RPEemo

cto severe pain.

Refer to Paediatric
emergency

(62) Inj. Voveron 1 ampule stat in

नेत्र ईश्वरीय सर्वश्रेष्ठ उपहार है जिनका मनुष्य जीवन में दान करना परमश्रेष्ठ है।
इनकी पुर्ण रक्षा कीजिए ताकि ये आपकी रक्षा कर सकें।

Eyes are God's most precious gift to man kind. Take full care of them
So that they can take care of you

7/5/2017

Review on 20/6/2017 Arora

ब० रो० वि० कार्ड
O.P.D. Card

9



अनुभाग व दिन
Section and Day
मंगलवार व शुक्रवार

V

कमरा नंबर
Cabin No.

डा० राजेन्द्र प्रसाद नेत्र विज्ञान केन्द्र,

अ० भा० आयु० सं०
Dr. Rajendra Prasad
A.I.I.M.S., New Delhi-1

यु एच आई डी संख्या
UHID No.

रोगी का नाम
Name of the patient

DR. RAJENDRA PRASAD CENTRE FOR OPHTHALMIC SCIENCES

UHID: 102570210
Dept. No.: 20170050017235
BAHAR ASULAM
S/O: ABULKASAM

Date: 06/10/2017
General
RPC OPD-Dr. Rachna Meel
Unit-V TUE, FRI
Room No.: 33

Address: KHUTHKUTHI SHANTI VILLAGE DIST. DIBRU, ASSAM, INDIA
Mobile: 9531263491

दिनांक DATE	निदान DIAGNOSIS
----------------	--------------------

उपचार Treatment

08 OCT 2017 5 cycles of chemo completed

MRI done

Residual disease
ON extension till apex
thickening

NRC - Dr. Harpreet to discuss Dr. Sangam
chemo for residual
Orbital mass ①
+ ON thickening extent

To Plan chemotherapy accordingly

Rachna

wed
12:00
53

116 2:00

कृपया इस कार्ड को सुरक्षित रखें तथा अस्पताल में दिखाने के समय हर वक्त साथ लायें।
Kindly keep this Card safely and bring it on your follow-up visits.

- धूम्रपान निषेध
- कूड़ा कर्कट केवल कूड़ेदान में ही डालें
- शूकिये नहीं

दिनांक - Date

उपचार- Treatment

~~18/10/17~~ Sat 10am ward 1B

18/10/17 For NRC
C/S/D SR Radiology in NRC
(31/10/17) ~~Repeat~~ (Post 5 chemo - MRI)

↳ No sign. reduction in size

Extracocular muscle
ON a up to apex
Retroorbital fat } involvement ⊕

No progression in mass

F/V in (#33) : Dr. Roshna Mool
Tue/Fri, 9 AM
GJ

नेत्र ईश्वरीय सर्वश्रेष्ठ उपहार है जिनका मनुष्य जीवन में दान करना परमश्रेष्ठ है।
इनकी पुर्ण रक्षा कीजिए ताकि ये आपकी रक्षा कर सकें।
Eyes are God's most precious gift to man kind. Take full care of them
So that they can take care of you

ब० रो० वि० कार्ड
O.P.D. Card



अनुभाग व दिन
Section and Day
मंगलवार व शुक्रवार
Tuesday & Friday

197560

कमरा नंबर
Cabin No.

डा० राजेन्द्र प्रसाद नेत्र चिकित्सक
अ० भा० आयु० सं०, नए दिल्ली
Dr. Rajendra Prasad Centre for Ophthalmic Sciences
A.I.I.M.S., New Delhi-110 029
यु एच आई डी संख्या
UHID No.

DR. RAJENDRA PRASAD CENTRE FOR OPHTHALMIC SCIENCES

UHID: 102570210
Dept. No.: 20170050017235
BAHAR ASULAM
S/O: ABULKASAM

BY/M

Date: 15/09/2017
General
RPC OPD-Dr. Rachna Meel
Unit-V
Room No.: 33
TUE, FRI

Address: KHUTHKHUTHI SHANTI VILLAGE DIST. DIBRU, ASSAM, INDIA
Mobile: 9531263491



रोगी का नाम
Name of the patient

दिनांक DATE	निदान DIAGNOSIS
	उपचार Treatment
10 SEP 2017	
15 SEP 2017	flu after 1 wk on Tue at 9:00 am in OPD no 33.
	HPE Reports 7th floor Pathology 753 Unit
	Dr. Sameer Bakshi Please Help. Pt. has lost OPD cards - awaiting chemotherapy

LB
Medical
19/9/17

2579

कृपया इस कार्ड को सुरक्षित रखें तथा अस्पताल में दिखाने के समय हर वक्त साथ लायें।
Kindly keep this Card safely and bring it on your follow-up visits.

- धूम्रपान निषेध
- कूड़ा कर्कट केवल कूड़ेदान में ही डालें
- शुकिये नहीं

ब० रो० वि० कार्ड
O.P.D. Card



अनुभाग व दिन
Section and Day
मंगलवार व शुक्रवार
Tuesday & Friday

कमरा नंबर
Cabin No.

197560

डा० राजेन्द्र प्रसाद नेत्र चिकित्सालय
अ० भा० आयु० सं०, नए दिल्ली
Dr. Rajendra Prasad Centre
A.I.I.M.S., New Delhi-110
यु एच आई डी संख्या
UHID No.

DR. RAJENDRA PRASAD CENTRE FOR OPHTHALMIC SCIENCES

UHID: 102570210
Dept. No.: 20170050017235
BAHAR ASULAM
S/O: ABULKASAM

Date: 15/09/2017
General
RPC OPD-Dr. Rachna Meel
Unit-V
TUE, FRI
Room No.: 33

Address: KHUTHKHUTHI SHANTI VILLAGE DIST DIBRU, ASSAM, INDIA
Mobile: 9531263491

रोगी का नाम
Name of the patient

दिनांक DATE	निदान DIAGNOSIS
	उपचार Treatment
10 SEP 2017	
15 SEP 2017	flu after 2 wks on Tue at 9:00 am in OPD no 33.
19/9/17	HPE Reports 7th Floor Pathology 753 Dr. Sameer Bakshi Please Help. Pt. has lost OPD cards - awaiting chemotherapy

कृपया इस कार्ड को सुरक्षित रखें तथा अस्पताल में दिखाने के समय हर वक्त साथ लायें।
Kindly keep this Card safely and bring it on your follow-up visits.

- धूपपान निषेध
- कूड़ा कर्कट केवल कूड़ेदान में ही डालें
- थूकिये नहीं

₹ 2579

29 SEP 2017

→ Has received 5 cycle of chemo
for extraocular Rb
Due for 6th cycle

To Review after 6th cycle of MRI
for date for enucleation & old MRI
& ~~find~~

Review

MRI to assess
Residual disease

MRI Orbital cuts 2mm
with CE fat suppressed
Oblique sagittal cuts

Dochoo

(116)

V. Mishra

→ Accommodation in
Sharamchala.

नेत्र ईश्वरीय सर्वश्रेष्ठ उपहार है जिनका मनुष्य जीवन में दान करना परमश्रेष्ठ है।
इनकी पूर्ण रक्षा कीजिए ताकि ये आपकी रक्षा कर सकें।

Eyes are God's most precious gift to man kind. Take full care of them
So that they can take care of you

①

ब० रो० वि० कार्ड O.P.D. Card



नेत्र अग्रणी उपचार है
जो आप ही दे सकते हैं

अनुभाग व दिन
Section and Day
मंगलवार व शुक्रवार
Tuesday & Friday

V

कमरा नंबर
Cabin No.

डा० राजेन्द्र प्रसाद नेत्र विज्ञान केन्द्र,
अ० भा० आयु० सं०, नई दिल्ली - ११००२९
Dr. Rajendra Prasad Centre for Ophthalmic Sciences
A.I.I.M.S., New Delhi-110029

यु एच आई डी संख्या
UHID No.

आचार्य प्रदीप शर्मा का एकक
Prof Pradeep Sharma's Unit

रोगी का नाम Name of the patient	पुत्र/पुत्री/पत्नी S/D/W	लिंग Sex	आयु Age	पता Address
Babar Aslam		m	8yr	

दिनांक DATE	निदान DIAGNOSIS
28/7/17	उपचार Treatment EUA done by Dr. Raulna

Kindly collect
HPE reports
from 7th floor
Pathology

② Physioical

④ No treatable/manifest lesion noted

Advice

Date for Enucleation
after 1 more cycles
(come to OPD ③
after 5 weeks)

DoA
3/10/17
35B-9:0

कृपया इस कार्ड को सुरक्षित रखें तथा अस्पताल में दिखाने के समय हर वक्त साथ लायें।
Kindly keep this Card safely and bring it on your follow-up visits.

१. धूम्रपान निषेध २. कूड़ा कर्कट केवल कूड़ेदान में ही डालें ३. थूकिये नहीं

ब० रो० वि० कार्ड
O.P.D. Card



अनुभाग व दिन
Section and Day
मंगलवार व शुक्रवार
Tuesday & Friday

कमरा नंबर
Cabin No.

डा० राजेन्द्र प्रसाद
अ० भा० आयु० र
Dr. Rajendra Prasad
A.I.I.M.S., New De
यु एच आई डी स
UHID No.

रोगी
Name of

Bahar

दिनांक
DATE

निदान
DIAGNOSIS

उपचार Treatment

05/11/17

CSB SR Radiology in MRC,

Ref of (P) RB (Physical Eye)

Chemotherapy → 4 cycles
4/7/17

Radio → X

Now, MRI Orbit & Brain of 29/Jul/17

T₁ weighted image → hyperintense lesion noted

Dr. Pushkar Rao

कृपया इस कार्ड को सुरक्षित रखें तथा अस्पताल में दिखाने के समय हर वक्त साथ लायें।
Kindly keep this Card safely and bring it on your follow-up visits.

१. धूम्रपान निषेध २. कूड़ा कर्कट केवल कूड़ेदान में ही डालें ३. थूकिये नहीं

दिनांक - Date

उपचार- Treatment

- Hypertensive T2W image S/O High
- Some heterogenous enhancement
- Residual ^{mass} Retrobulbar, Intraconal part present.

Anesthesia note (8/20/14)
 24/2/14 (Dr. Manpreet / Anest)
 (RB) → EVA.
 No active URI
 active Pugh. b/c clear
 S/S (2)
 (D) O₂ No sero CMB# 2.0
 (M) O₂ No sero
 (R) 100% O₂
 All (D) No till fully awake
 (2) (L) let's see by hand
 (3) monitor vitals from 8:05
 Anest

Impression:-

Adv:- (2) OP could be considered option
 (Extension OP) at 2p today
 (EB) Today 1/3 in
 OR

Dilated fundus exam of U - (2) (3) →

(33) Friday नेत्र ईश्वरीय सर्वश्रेष्ठ उपहार है जिनका मनुष्य जीवन में दान करना परमश्रेष्ठ है।
 इनकी पूर्ण रक्षा कीजिए ताकि ये आपकी रक्षा कर सकें। On Indirect
 Eyes are God's most precious gift to man kind. Take full care of them
 So that they can take care of you ophthalmoscopy
 But given in (2) plaque in (4) NO evidence of RB

ब. रो. वि. कार्ड

दृष्टि

अनुभाग व दिन

O.P.

DR. RAJENDRA PRASAD CENTRE FOR OPHTHALMIC SCIENCES

कक्षा नंबर
Cabin No.

डा० राजेन्द्र प्रसाद
अ०भा०आयु०सं०, न
Dr. Rajendra Prasad
A.I.I.M.S., New Delhi
यु एच आई डी सं
UHID No.

UHID: 102570210
Dept. No.: 20170050017235
BAHAR ASULAM
S/O: ABULKASAM

Date: 07/02/2017
General
₹10
RPC OPD-Dr. Tushar
Agarwal
Unit-III TUE, FRI
Room No.: 1

Address: KHUTHKHUTHI SHANTI VILLAGE DIST DIBRU, ASSAM, INDIA
Mobile: 9531263491



रोगी का नाम
Name of the Patient S/D/W Sex Age Address

दिनांक
DATE

निदान
DIAGNOSIS

(R) Prognosis

उपचार Treatment

~~R 68/38~~
~~13/2/2017~~

~~Prognosis, Ray. N. Prognosis~~
~~open 1/5.~~

Vn
(unaided) PL-Vc
6/6.

(30)

7/2/2017

(R) scaplylomatous globe
c. capacity c.
seeing


2 Max lesion
affecting globe
choroid.

(not peep till low gain)
e Retrobulbar cystic
lesion in orbit

(136)

USG RE for P/S.

Fu on boundary
e report



को सुरक्षित रखें तथा अस्पताल में दिखाने के समय हर वक्त साथ लायें।
keep this Card safely and bring it on your follow-up visits.

बेध २. कूड़ा कर्कट केवल कूड़ेदान में ही डालें ३. थूकिये नहीं

ब० रो० वि० कार्ड
O.P.D.

डा० राजेन्द्र प्रसाद नेत्र विज्ञान
अ० भा० आयु० सं०, नई दिल्ली
Dr. Rajendra Prasad Centre for
A.I.I.M.S., New Delhi-110029

यु एच आई डी संख्या
UHID No.

DR. RAJENDRA PRASAD CENTRE FOR OPHTHALMIC SCIENCES

UHID: 102570210
Dept. No.: 20170050917235
BAHAR ASULAM
S/O: ABULKASAM

Date: 20/10/2017
RPC OPD-Dr. Rachna
Unit-V
Room No.: 33
TUE, FRI

Address: KHUTHKHUTHI SHANTI VILLAGE DIST DIBRU, ASSAM, INDIA
Mobile: 9531263491

रोगी का नाम
Name of the patient

Sex Age पता
Address

②

दिनांक DATE	निदान DIAGNOSIS	उपचार Treatment	
20 OCT 2017		DOA for limited emulsification	Reviewed B.O.C chemo
24 OCT 2017		early date Please Rachna	last 0 21/9/2017
	35A		

Flu OR for admission

कृपया इस कार्ड को सुरक्षित रखें तथा अस्पताल में दिखाने के समय हर वक्त साथ लायें।
Kindly keep this Card safely and bring it on your follow-up visits.

- धूम्रपान निषेध
- कूड़ा कर्कट केवल कूड़ेदान में ही डालें
- शूकिये नहीं

Indus disc & maula healthy

RPH-061117032 102570210



BAHARASULAM

Dr. Rajendra Prasad Centre For Ophthalmic Sciences
ALL INDIA INSTITUTE OF MEDICAL SCIENCES (AIIMS), New Delhi,
Discharge Report
 PROVISIONAL DISCHARGE CERTIFICATE

17-1453
3/11/17

UHID :	102570210	Cr No:	R-036884-17
Name:	Mr BAHAR ASULAM	Department:	R. P. Centre (Eye Centre)
Age/Sex:	8 years 8 mons 24 days / Male	Unit:	Unit-V
Ward Name:	1B	Bed No.:	146
Address:	KHUTHKHUTHI SHANTI VILLAGE DIST. DIBRU, ASSAM, INDIA	Drug Allergy, if any :- <input type="checkbox"/>	
Mobile No:	9531263491		
Date of Admission:	31/10/2017 10:59:06 AM		
Date of Discharge :	03/11/2017 08:22:00 AM		

Diagnosis	.RE POST CHEMOREDUCTION EORB WITH PTHISIS LE WNL
ICD	.C69.2Description-Malignant neoplasm: Retina

Investigation	Systemic	.NIL	Ocular	.VA .RE NO PL LE 6/6
----------------------	-----------------	------	---------------	----------------------------

Treatment/Operative Procedure	Surgeon	.DR ASHA Dr Rachna Meel	Surgery	.RE EXTENDED ENUCLEATION IMPLANT UNDER GA
Date	03/11/2017			Mules implant 16 mm conformer pt

Condition at Discharge	Vision	.RE NO PL	IOP	.RE ENUCLEATED EYE
	Anterior Seg.	.RE LID EDEMA PRESENT ENUCLEATED EYE	Posterior Seg.	.RE NO GLOW

Advice During Discharge	Oral	SYP OPHTHALM 20mg QD NBT 2 days SYP IBUGESIC 5 ML TDS SYP DIGENE 3 ML TDS) x/week	Topical	.RE E/D MILFLOX QID E/D REFRESH TEARS 6T/D E/O CIPLOX TDS FOR LOCAL APPLICATION
	Follow Up	.DR RACHNA MEEL AFTER 1 WEEK IN ROOM NO:33 ON TUESDAY/FRIDAY AT 9AM	Position	

collect HPE reports x/week
 Syp Argemontin 5ml BID *
 Mother screening done -
 Repeat eye -
 EVA LG
 Indus disc & mark healthy

Prepared By: Dr. Sreeshankar S S RPC
 Signature Of Senior Resident
 Date & Time



**Dr. Rajendra Prasad Centre For Ophthalmic Sciences
ALL INDIA INSTITUTE OF MEDICAL SCIENCES
(AIIMS), New Delhi,**

**Discharge Report
PROVISIONAL DISCHARGE CERTIFICATE**

UHID : 102570210
 Name: Mr BAHAR ASULAM
 Age/Sex: 8 years 1 mon / Male
 Ward Name: 1B
 Address: KHUTHKHUTHI SHANTI VILLAGE
 DIST. DIBRU, ASSAM, INDIA
 Mobile No: 9531263491
 Date of Admission: 21/02/2017 11:48:46 AM
 Date of Discharge: 06/03/2017 05:37:00 PM

Cr No: R-006692-17
 Department: R. P. Centre (Eye Centre)
 Unit: Unit-V
 Bed No.: 148

Drug Allergy, if any :- []

17-325
 7/3/17

Diagnosis

ICD .RE PROPTOSIS WITH CILIARY STAPHYLOMA
 ,H02.8Description-Other specified disorders of eyelid

RRB

usg of Leucocelae mass & calcification to RB.

Investigation

Systemic .NO H/O SYSTEMIC ILLNESS
 Ocular .RE- NO PL
 LE-6/6

Treatment/Operative Procedure

Surgeon .DR.RACHNA MEEL
 Date 06/03/2017
 Surgery .RE ~~EXCISION~~ ^{INCISION} BIOPSY IN GA
 LE EUA --WNL

Condition at Discharge

Vision - No PL
 - watery discharge
 Anterior Seg. - Proptosis ⊕
 - ⊕ Staphyloma
 AC - Shallow
 IOP - 12y ↑
 Posterior Seg. -

7/5/17

Advice During Discharge

Oral TAB.AUGMENTIN 375 mg BD ^{5 days}
 TAB RANTAC 75 mg BD
 Follow Up .WITH DR.RACHNA MEEL IN ROOM
 no.33 AFTER 1 WEEK ON TUES/FRID
 at 09:00am
 Topical @ 4x4 D MOXICIP QID
 E/D REFRESH TEARS 6T/D

→ Collect histopath Report from 7th floor
 after 1 week

RK

Prepared By: Dr. Rahul Kumar Bafna RPC



J-16, Hauz Khas Enclave, Main Aurobindo Marg, New Delhi - 110016

Phone No. : 011-49515253 - (30 Lines), Email : drgulatiimaging@gmail.com

Website : www.drgulatiimaging.in

PATIENT'S NAME: BAHAR ASULAM	AGE/SEX: 8Y/M
REF. BY: CAN KIDS	REG. ID: BAM0568
CONTRAST USED : YES	EXAM. DATE:29-Jun-2017

MR imaging of Orbits and Brain was performed in sagittal, parasagittal, coronal and axial plane using dedicated synergy head coil on 3.0 Tesla MRI. SE, TSE, SPIR and FLAIR sequences were used to obtain FATSAT, T1 & T2 weighted images. Post contrast scans were obtained after giving I/V Gd-DTPA. (2ml of gadolinium was administered I.V.). No immediate contrast adverse reaction was noted.

Status: Treated case of bilateral Retinoblastoma

Right Orbit

Right eye ball is small, mildly irregular in outline and atrophic with loss of differentiation of anterior & posterior chamber suggestive of phthisis bulbi

A well defined, heterogenous mass lesion of size 18 x 18mm (AP x TR) is noted in right orbit involving conal compartment in close approximation to the posterior surface of globe. It shows heterogenous contrast enhancement. There is thickening and enhancement of bilateral retinal leaves noted. The mass lesion is encasing the optic nerve in its intraorbital part. Small mass lesion of size 7 x 7mm is noted at orbital apex showing heterogenous contrast enhancement. The optic nerve is thickened in its intraorbital and intracanalicular part, however, no abnormal enhancement of optic chiasma noted.

Orbital bony margins are normal.

Left Orbit

Orbital bony margins are normal. Two subcentimetric plaque like lesions are noted in left eye globe in vitreous compartment, lateral to optic disc and along medial wall. Subtle contrast enhancement is evident within them.

There is no proptosis. Left retro bulbar compartment are normal. Bilateral extra ocular muscles appear normal. The left optic nerve appears normal in integrity and signal intensity. Optic chiasm appears normal.

Brain

The brain parenchyma appears normal in the supratentorial compartment. There is no mass lesion/ infarct or any active granulomatous lesion. There is no mass effect or midline shift. No obvious vascular lesion.

Brain stem and bilateral cerebellar hemispheres appear normal. Bilateral CP angles are normal. No CP angle mass seen. Bilateral 7th & 8th nerve complexes are normal.

Cont...2



J-16, Hauz Khas Enclave, Main Aurobindo Marg, New Delhi - 110016
Phone No. : 011-49515253 - (30 Lines), Email : drgulatiimaging@gmail.com
Website : www.drgulatiimaging.in

PATIENT'S NAME: BAHAR ASULAM	AGE/SEX: 8/M
REF. BY: A I I M S	REG. ID: BAM2412
CONTRAST USED : YES	EXAM. DATE: 03-OCT-2017

MR imaging of Orbits and Brain was performed in sagittal, parasagittal, coronal and axial plane using dedicated synergy head coil on 3.0 Tesla MRI. SE, TSE, SPIR and FLAIR sequences were used to obtain FATSAT, T1 & T2 weighted images. Post contrast scans were obtained after giving I/V Gd-DTPA. (2ml of gadolinium was administered I.V.). No immediate contrast adverse reaction was noted.

Status: Treated case of bilateral Retinoblastoma

Right Orbit

Right eye ball is small, irregular in outline and atrophic with blooming on FFE (calcification) suggestive of phthisis bulbi

An irregular, heterogenous mass lesion in right orbit which is T1W iso and T2W hypointense and shows post contrast enhancement. The mass has extra-ocular and retrobulbar extension with involvement of both intra and extraconal compartment.

Optic nerve is thickened and shows signal alteration with contrast enhancement till the intracranial for segment. Optic chiasma is normal.

Orbital bony margins are normal.

Left Orbit

Orbital bony margins are normal. Two subcentimetric plaque like lesions are noted in left eye globe in vitreous compartment, lateral to optic disc and along medial wall. Subtle contrast enhancement is evident within them.

There is no proptosis. Left retro bulbar compartment are normal. Bilateral extra ocular muscles appear normal. The left optic nerve appears normal in integrity and signal intensity. Optic chiasm appears normal.

Brain

The brain parenchyma appears normal in the supratentorial compartment. There is no mass lesion/ infarct or any active granulomatous lesion. There is no mass effect or midline shift. No obvious vascular lesion.

Brain stem and bilateral cerebellar hemispheres appear normal. Bilateral CP angles are normal. No CP angle mass seen. Bilateral 7th & 8th nerve complexes are normal.

Cont...2



J-16, Hauz Khas Enclave, Main Aurobindo Marg, New Delhi - 110016

Phone No. : 011-49515253 - (30 Lines), Email : drgulatiimaging@gmail.com

Website : www.drgulatiimaging.in

PATIENT'S NAME: BAHAR ASULAM	AGE/SEX: 8/M
REF. BY: A I I M S	REG. ID: BAM2412
CONTRAST USED : YES	EXAM. DATE:03-OCT-2017

Post contrast scans reveal no significant abnormal parenchymal/ meningeal enhancement.

Sella turcica is normal in size. There is no sellar mass. Suprasellar and parasellar regions appear normal.

The lateral, third and fourth ventricles appear normal. Cortical sulci and bilateral sylvian fissures are normal.

CSF shows normal signal. There is no compression at the CV junction.

Note is made of left maxillary sinusitis.

IMPRESSION

- Right phthisis bulbi with heterogeneously enhancing mass lesion in right orbit with retrobulbar extension and optic nerve involvement till the intracanalicular segment.
- Two small plaque like subcentimetric lesions are also noted in left eye globe.
- MRI Brain within normal limits.

As compared to previous MRI scan dated 29.06.2017, there is no significant interval change. Please correlate clinicopathologically.

DR. PARVEEN GULATI, M.D
DMC. 3339


DR. ANKITA AGGARWAL
MD, DNB
Consultant (MCI. 10-36102)

JAI KALKA MAI

GSTIN : 07AAAF1757N1Z5

D.L. No.: 13(1419) 20, 21 & 20C

GST INVOICE

+ INDER MEDICOS +

P-3, NDMC MARKET, YUSUF SARAI, NEW DELHI-110 029

ALL DAYS
OPEN

CREDIT CARD
ACCEPTED

MEDICINES, SURGICALS & COSMETICS (RETAIL & WHOLESALE)

E-mail : indermedicosys@gmail.com

☎ 46665307, 46665308, 46665309, 9811081797, 9810874003 📞

★ In case you find any inadvertent error in the price charged.
★ Please bring this GST invoice for refund of difference.

ANTAR FORMS
AF
2017

QTY	PARTICULARS	BATCH NO.	EXP. DT.	GST	AMOUNT
30	SOLITEN-5MG TAB	EMS1979	09/19	12.0	804.00

Printed by : Anuraj Continuous Forms # 981114510, 913944330

no return of cutting & fridge item

DO ONE GOOD ACT A DAY

BILL NO. : 55910	DATE : 12/01/18	Total	804.00
PATIENT Ms/Mr. : ASMINA		CGST	39.38
ADDRESS :		SGST	39.38
Pres. by Dr. : AIIMS	Sign. SAHIL	Grand Total	735.00

1. No Return, No Exchange
2. All Disputes are subject to Delhi Jurisdiction only.

E&OE

11

Absent at 11:50 am

ब० रो० वि० कार्ड O.P.D. Card



अनुभाग व दिन
Section and Day
मंगलवार व शुक्रवार
Tuesday & Friday

कमरा नंबर
Cabin No.

डा० राजेन्द्र प्रसाद नेत्र विज्ञान केन्द्र,
अ० भा० आयु० सं०, नई दिल्ली - ११००२९
Dr. Rajendra Prasad Centre for Ophthalmic Sciences
A.I.I.M.S., New Delhi

DR. RAJENDRA PRASAD CENTRE FOR OPHTHALMIC SCIENCES

यु एच आई डी संख्या
UHID No.

UHID: 102570210
Dept. No.: 20170050017235
BAHAR ASULAM
S/O: ABULKASAM

Date: 09/01/2018
General
RPC OPD-Dr. Rachna Meel
Unit-V TUE, FRI
Room No.: 33

रोगी का नाम
Name of the

Address: KHUTHKHUTHI SHANTI VILLAGE DIST. DIBRU, ASSAM, INDIA
Mobile: 9531263491

दिनांक
DATE

DIAGNOSIS

उपचार Treatment

09 JAN 2018

(RC)

Completed EBRT in Dec. 2017
Chlorochol H M/S
Emit 1000
fresh tears
& 3 months

9/10/2018 (1 mth)

Review after EBRT

Rev 3 mos

Under Other eye next visit
Decharge

कृपया इस कार्ड को सुरक्षित रखें तथा अस्पताल में दिखाने के समय हर वक्त साथ लायें।
Kindly keep this Card safely and bring it on your follow-up visits.

- १. धूम्रपान निषेध २. कूड़ा कर्कट केवल कूड़ेदान में ही डालें ३. थूकिये नहीं

ভারতীয় নির্বাচন আয়োগ
ELECTION COMMISSION OF INDIA
ভোটার ফটো পরিচয় পত্র
ELECTOR PHOTO IDENTITY CARD

KZG1313662 



ভোটারের নাম / Elector's Name
আচমিনা বেগম
ACHAMINA BEGUM

সম্পর্কিত ব্যক্তির নাম / Relation Name
মঃ আবুল কাচিম আলী
MD ABUL KACHIM ALI

লিঙ্গ / Sex : মহিলা / Female

Date of Birth / Age : 34 Yrs

ঠিকানা : বাও/চবে-খটখাটা পাকা ফিল্ড, ধামা-বটখাটা,
মহকুমা - চিফু,
জিলা-কাৰ্বি অংলং, (আসম)
Address : VIII/Town-KHATKHATI PAKA FIELD,
P.S.-Khatkhati, Sub-Divn.-Diphu,
Dist.-KARBI ANGLONG, (Assam)

ELECTION COMMISSION
OF INDIA

Date: 01/10/13

Electoral Registration Officer

বিধানসভা সমষ্টিৰ নাম ও নাম : 17, বোকাজান
(উ:উ:তা)

Assembly Constituency : 17, Bokajan (ST)
No. and Name

খণ্ড নং ও নাম : 144, খটখাটা পৰ্ব্বক্ষিত হিন্দী
শুধু, খটখাটা (পোৰফিল্ড)

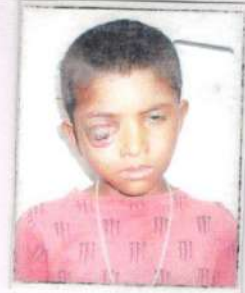Part No. and Name : 144, Khatkhati Poocefield
Hindi L.P.School(RW)

বিদ্যা : (ক) কেৱল এই খণ্ডটি থাকিব পাৰে কিন্তু ইয়াত কোনো
অন্যবিধ কাৰ্ডখন নথি কৰিব লাগিব। (খ) ইয়াত কোনো
অন্য কাৰ্ডখন থকা হ'লে ইয়াত ইয়াৰ নামেৰে
নথি কৰিব লাগিব। (গ) ইয়াত কোনো
অন্য কাৰ্ডখন থকা হ'লে ইয়াত ইয়াৰ নামেৰে
নথি কৰিব লাগিব।

Note: (a) Mere possession of this card is no guarantee that you
are elector in the current electoral roll. Please check your name
in the current electoral roll before every Election. (b) Date of birth
mentioned in this card shall not be treated as proof of age/
D.O.B. for any purpose other than registration in electoral roll.

31
13
10

सेवा में:-




UTTHAN TRUST

विषय:- मेरा बड़ा बच्चा बहार इस्लाम के इलाज के सम्बन्ध में मेरा नाम अस्मिना बेगम गांव खुटकुटी शान्ति गांव असम गुहाटी।

मेरा बच्चा जिसका नाम बहार इस्लाम जिसका उम्र 8 साल है। जो इस समय नेत्र कैंसर से पीड़ित है। जिसका इलाज एम्स आस्पताल में कैंसर के डाक्टर समीर के द्वारा इलाज किया जा रहा है। इलाज में काफी खर्चा आ रहा है। जबकि मैं एक धरलू महिला हूँ और मेरे पति भजदूर हैं जिनका वेतन इतना नहीं है कि हम अपने बच्चे का इलाज करा सकें। इसलिए अपने बच्चे को बचाने के लिए मैं अभिषेक तिवारी जी व UTTAHAN TRUST से विनती करती हूँ कि वो हमें मदद करें। इसके लिए मैं सदा UTTAHAN TRUST की आभारी रहूँगी।

नाम:- अस्मिना बेगम

DATE - 31-01-2018



Accepted

