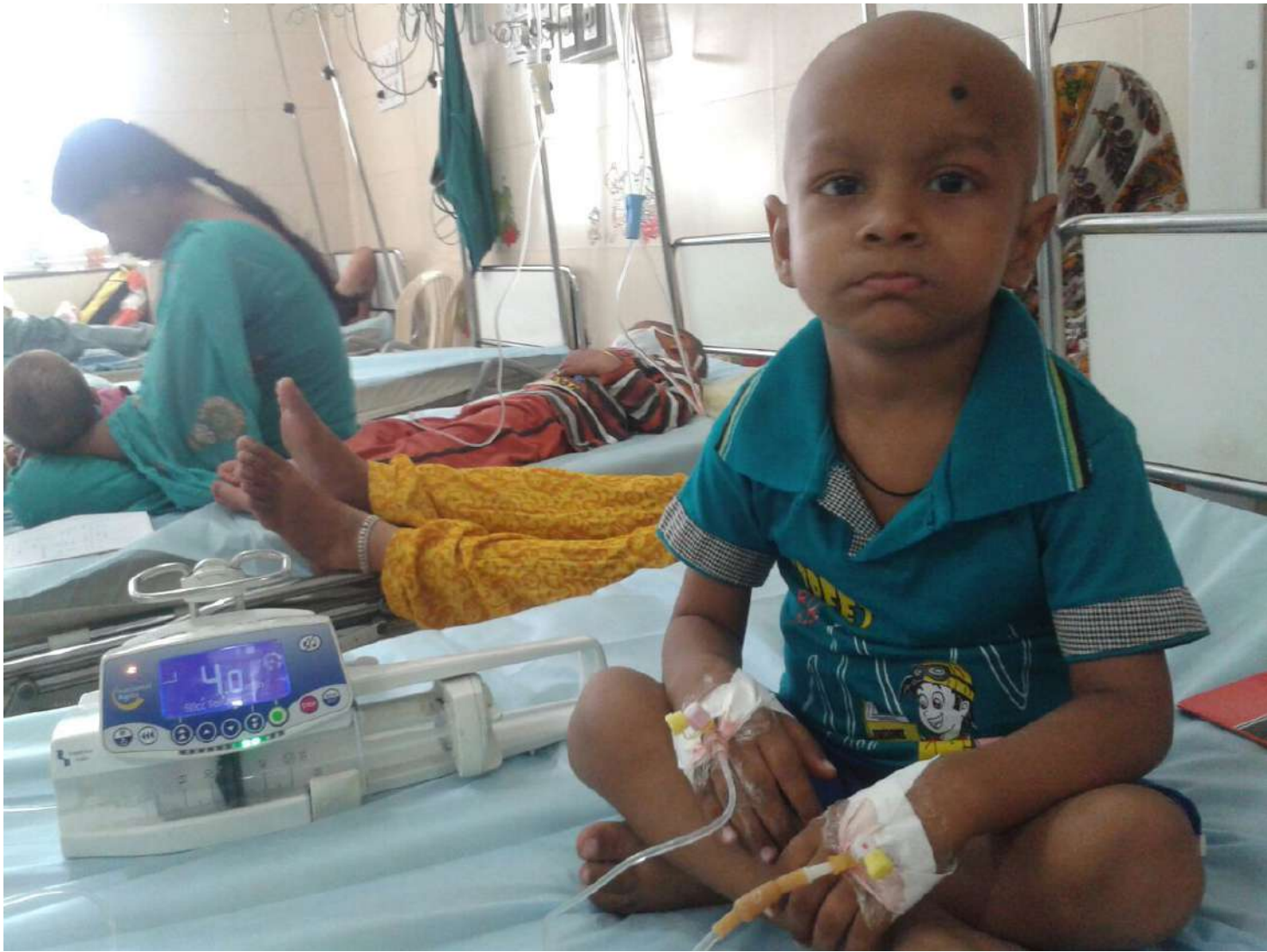
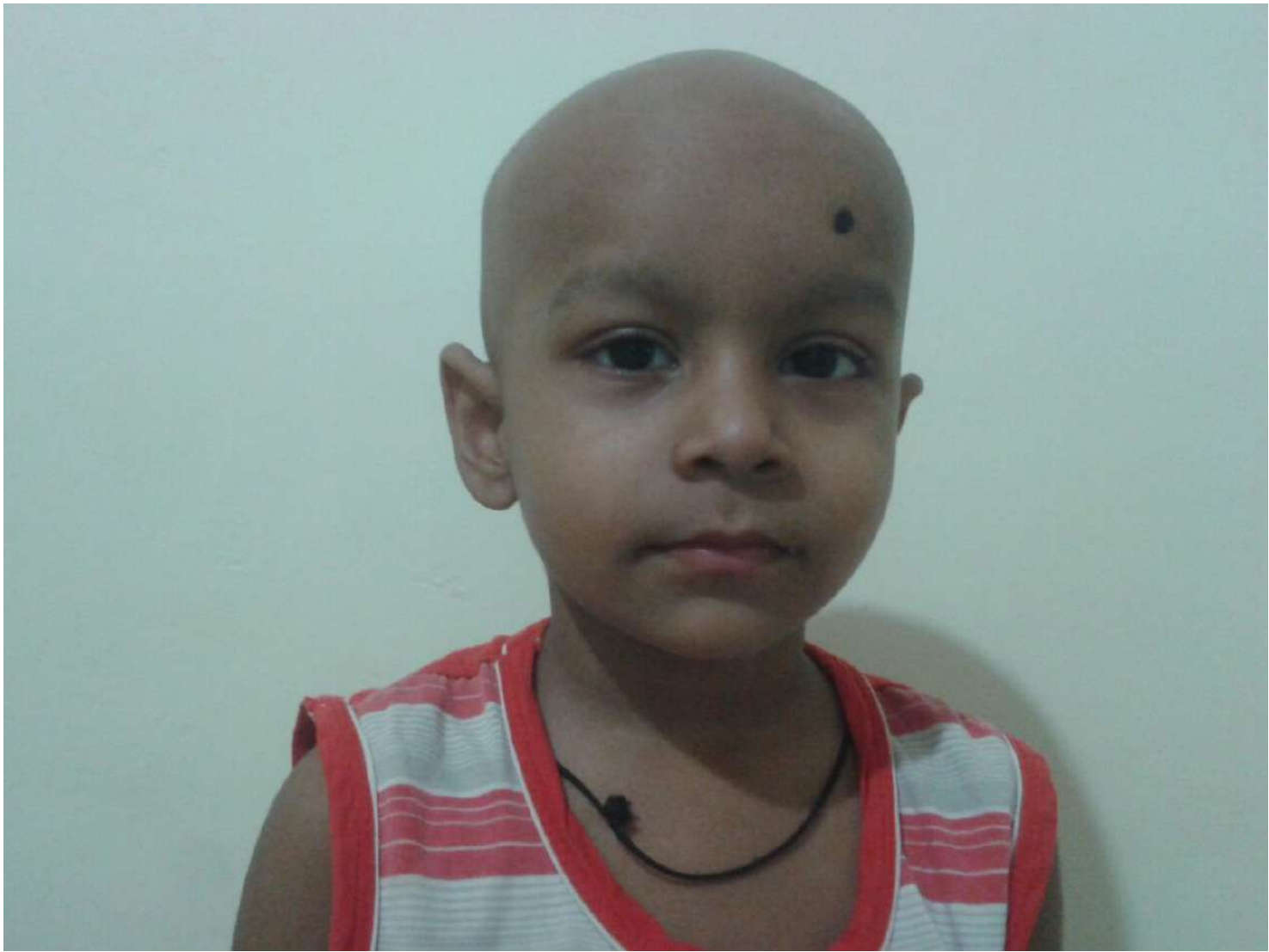
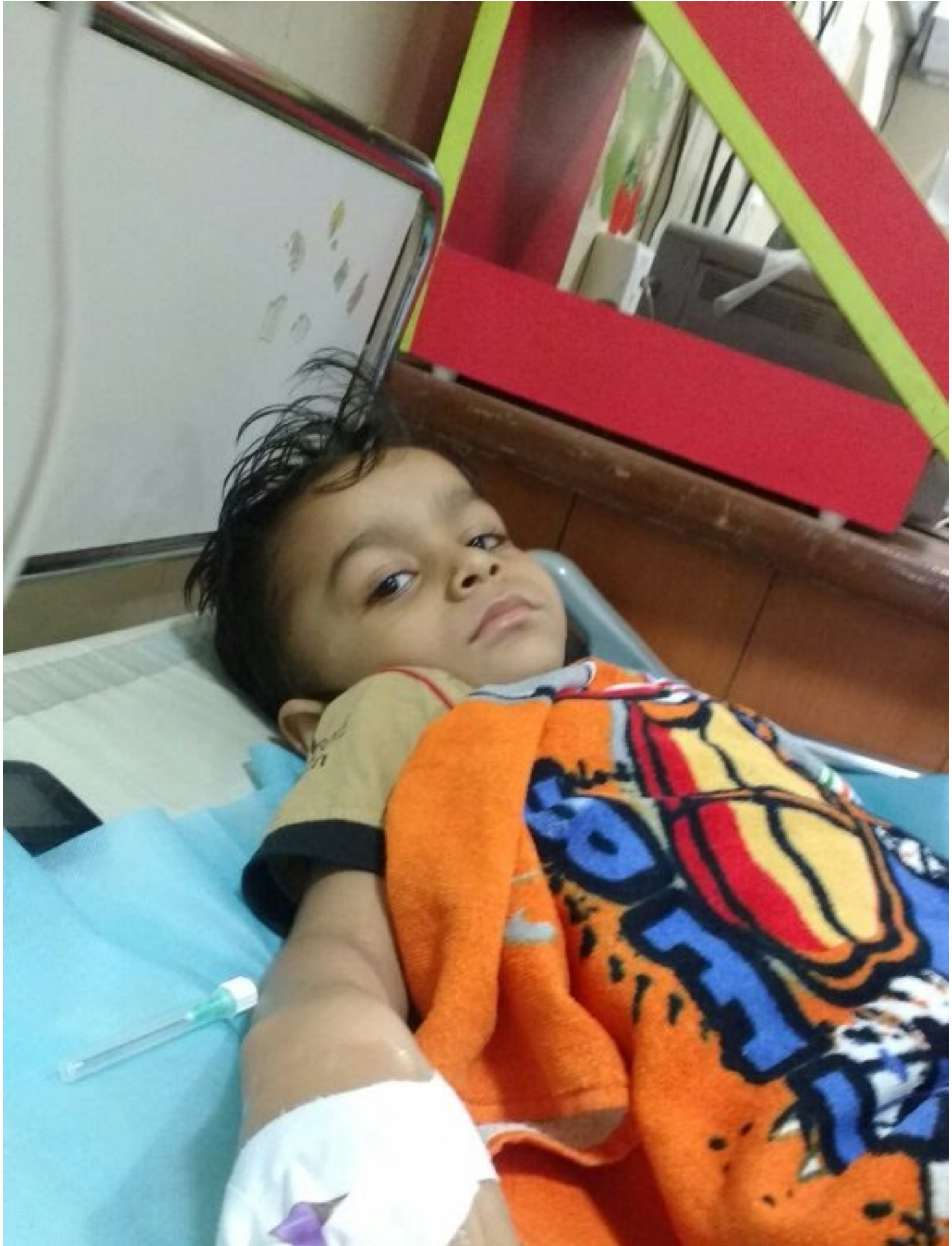





General
 PD UHID: 100905947
 Clinic No: P.ONCOLOGY OPD - 2016/P.ONCOLOGY OPD /43
 Name: ANAND KUMAR
 S/O ANIL KUMAR, 3Y 0M 20D, M
 Ph: 9431416181
 KALYAN PUR, DISTT- GAYA, BIHAR, INDIA
 DeptSeq: 1
 Dept: Paed
 Unit: Unit
 Room: 7
 F/16
 Days: WED,
 App. Date: 28/01/2017
 Appt. ID: 2017012800392

56

General
 ZO UHID: 100905947
 Clinic No: P.ONCOLOGY OPD - 2016/P.ONCOLOGY OPD /43
 Name: ANAND KUMAR
 S/O ANIL KUMAR, 3Y 10M 14D, M
 Ph: 9431416181
 KALYAN PUR, DISTT- GAYA, BIHAR, INDIA
 DeptSeq: 382
 Dept: Paediatric
 Unit: Unit-III
 Room: 7
 F/48
 Days: WED,SAT
 App. Date: 22/02/2017
 Appt. ID: 2017022204748

7

General
 ZO UHID: 100905947
 Clinic No: P.ONCOLOGY OPD - 2016/P.ONCOLOGY OPD /43
 Name: ANAND KUMAR
 S/O ANIL KUMAR, 3Y 11M 23D, M
 Ph: 9431416181
 KALYAN PUR, DISTT- GAYA, BIHAR, INDIA
 DeptSeq: 359
 Dept: Paediatric
 Unit: Unit-III
 Room: 7
 F/56
 Days: WED,
 App. Date: 01/04/2017
 Appt. ID: 2017040102620

stage IV NB.
 - post 6 cycles chemo + RT.
 Not-resectable

off on fever
 off on constipation
 ↓ weight over 1m.

latest PET CT → Metabolically active retroperitoneal mass + mets.

30

~~Child~~ probability
 → New symptomatology due to ↑ in lesions.

- Poor prognosis explained: (CD/w Dr R. Seth).

CBC-8.5/8.13/2.10
 EFT/RFT-L

- cap Tenozobanor / Meth
 Topotecan / meth

- Ref to Prof C.S. Bal for MIBG therapy. (Nuclear medicine)
- Cap Sotret (20mg) 2 cap BD x 15d.
- R/A 1 week

Falser outcome explained regarding
 outcome & Addressed antineoplastic likely
 despite these means

- Cap syr Calcipol 7.5ml PO
- TDS x 3d flb SOS
- septran to continue

Hydrate



अ० भा० आ० सं० अस्पताल / A.I.I.M.S. HOSPITAL
बहिरंग रोगी विभाग / Out Patient Department

शुभ्रकृतं वासना नैः / SMOKING IS PROHIBITED IN HOSPITAL PREMISES

सर्वकार्यं बहु परिकल्पनं

एकक/Unit
विभाग/Dept.
नाम

General
FO
Clinic No: F.ONCOLOGY OPD - 2016/F.ONCOLOGY OPD /43
Name: ANAND KUMAR
S/O ANIL KUMAR, Jy 13M 270, M
Ph: 9431416181
KALYAN PUR, DISTT- GAYA, BIHAR, INDIA
App. ID: 2017040509744

DeptSeq: 408
Dept: Paediatrics
Unit: Unit-III
Room: 7
F/35
Days: WED,SAT
App. Date: 05/04/2017

OPR-6

1 No/O.P.D. Regn. No.
पता/Address

निदान/Diagnosis

Relap Refractory stage IV NB

दिनांक/Date
(44)

उपचार/Treatment

Details in prev card dated 1/4/17.

- Rx.
- Cap Temozolamide 100mg OD x 5d }
(150mg/m²/day)
 - Inj Topotecan 0.5mg IV OD x 5d. }
 - Cap Sotret (20mg) 2 cap BD x 10d
- H.

Thursday
2pm

CLEAN AND GREEN AIIMS / एम्स का यही संकल्प, स्वच्छता से काया कल्प
अंगदान-जीवन का बहुमूल्य उपहार / ORGAN DONATION - A GIFT OF LIFE
O.R.B.O., AIIMS, 26588360, 26593444, www.orbo.org Helpline - 1060 (24 hrs service)

की किरानों पर देवे PAYABLE AT ALL BRANCHES
D D M M Y Y Y Y
RECEIVED ONLY



अ० भा० आ० सं० अस्पताल / A.I.I.M.S. HOSPITAL
बहिरंग रोगी विभाग / Out Patient Department

अस्पताल के अन्दर धूम्रपान मना है। / SMOKING IS PROHIBITED IN HOSPITAL PREMISES.
MON, WED

OPR-6

एकक/Unit: 2017/020/0000529
विभाग/Dept: नो. 100905947

नाम/Name	पिता/पुत्र/पत्नी/पुत्री F / S / W / D of	लिंग Sex	आयु Age	पता/Address
ANAND KUMAR	S/O: ANIL KUMAR	पुरुष M	3 वर्ष Y III महिना M 25 दिन D	KALYAN PUR, DISTT- GAYA, BIHAR, INDIA M: 9431416181

निदान/Diagnosis: Neuroblastoma

दिनांक/Date: उपचार/Treatment
presented with pain abdomen
Diagnosed as Neuroblastoma (27/1/15)

Registration Time: 08:30 AM-10:30 AM
Done By: RAK OPD/11069
Room No. 59A, Ground Floor (तल मंजिल)
03-04-2017 10:00: 5 AM
TO TAKE APPOINTMENT NUMBER THROUGH PHONE, DIAL: 011-65900669
DO NOT TAKE APPOINTMENT NUMBER THROUGH PHONE, DIAL: 011-65900669
फोन के माध्यम से अपॉइंटमेंट नंबर लेने के लिए, डायल : 011-65900669
Doctor may not be available. However you may be seen by some of the doctors in the Department (FDGN/724/15)
आपके डॉक्टर के उपलब्ध न होने पर, आपको विभाग में अन्य किसी डॉक्टर द्वारा देखा जा सकता है।

FDG PET (8/5/15) = metabolically active abdominal mass.
± pelvic LN metastases.
↓
Received 6 cycles chemotherapy.
↓
RT. - 10#

FDG PET (29/3/17) = metabolically active retroperitoneal mass residual primary with metastases to abdominopelvic LN ± extensive marrow.
Size 7 x 12.5 x 12.9 cm

MIBG Scan (19/8/16) = heterogenous soft tissue mass.
(MIBG-D-SP-12-928-16) (10.8 x 6.1) cm involving whole abdomen.
encasing retroperitoneal vessels ± Calcification.

Adv
Optim. A.C.S. - Mar, [131I] MIBG Scan.
of primary therapy. See

1 of 1

CLEAN AND GREEN AIIMS / एम्स का यही संकल्प, स्वच्छता से कार्या कल्प
अंगदान-जीवन का बहुमूल्य उपहार / ORGAN DONATION - A GIFT OF LIFE
O.R.B.O., AIIMS, 26588360, 26593444, www.orbo.org Helpline - 1060 (24 hrs service)

सभी शाखाओं पर वेध PAYABLE AT ALL BRANCHES
DDMMYYYY
या धारक को OR BEARER

आचार्य निवेशक, एनएच विहार, फेज-1, दिल्ली
Acharya Niketan, Mayapuri Vihar, Phase-1, DELHI - 110091
RTGS/NEFT IFS Code : PUNB0622100



DEPARTMENT OF RADIO-DIAGNOSIS
All India Institute of Medical Sciences (AIIMS)
Ansari Nagar, New Delhi - 110029

Patient Name: ANAND KUMAR Sex: M Age: 3Y
Patient ID: RAD103569 Report state: Signed-off
OPD/Ward: Pediatrics Unit 2/OPD
EXAMINATION DESCRIPTION: PERFORMED ON: CR No.:
CT WHOLE ABDOMEN (IV) 29 10 2015 11 56 100905947

Admitting diagnosis:

Known case of neuroblastoma, completed 5 cycles of chemotherapy

Previous scans done outside

Report:

CECT ABDOMEN

CT scan of the abdomen was performed with oral and IV contrast administration using 24x0.6mm collimation

A large heterogenous soft tissue attenuation mass of size approx. 9.3 x 4.9 x 9.8cm (MLXAPXCC) is noted in midline in retroperitoneal region extending from L1 to L5 vertebrae. Few hypodense areas and multiple coarse calcific foci are present within the mass. The mass is encasing the infrarenal aorta, inferior mesenteric artery, an accessory left renal artery without causing any narrowing in the calibre and displacing the IVC posterolaterally towards right. Small bowel loops are displaced anteriorly by the mass. prevertebral fat plane is maintained and no e/o any intraspinal extension is noted. Bilateral ureters are displaced laterally and no hydronephrosis is noted. Multiple small subcentimetric bilateral common iliac and external iliac lymph nodes are noted with calcification within, average size 7x5mm. Mild ascitis is present in left iliac fossa.

Liver is normal in size and attenuation. No focal lesion / IHBRD seen.

Hepatic veins and portal vein are normal.

Gall Bladder is normal, multiple calculi are present within the GB s/o cholelithiasis. CBD is not dilated.

Spleen is normal in size, shape and outlines. No focal lesion. Splenic vein is of normal caliber.

Pancreas is normal in size and attenuation. SMA and SMV are normal.

Both kidneys are normal in size, shape, outline and attenuation. No hydronephrosis or calculus.

Adrenals are normal.

Urinary Bladder is normal.

Bones are normal.

Sections obtained through lower chest are unremarkable.

Impression:

Known case of neuroblastoma on chemotherapy shows:

A large soft tissue attenuating retroperitoneal mass with internal calcifications and causing encasement of the infrarenal aorta, IMA and its branches as described with few calcified b/l external and common iliac lymph nodes with mild ascitis.

On comparison with previous CT dated 04/04/2015 done outside, there is mild reduction in the size of the mass and mass and the retroperitoneal lymph nodes shows calcification in the current scan.

POC-113/15

10



अ० भा० आ० सं० अस्पताल / A.I.I.M.S. HOSPITAL बहिरंग रोगी विभाग / Out Patient Department

अस्पताल के अन्दर धूम्रपान मना है। / SMOKING PROHIBITED

L PREMISES

OPR-6

बहिर्गम्य धूम्रपान मना है।

एम्ब/Unit

विभाग/Dept.

रोगी/Name



CHD: 100905947

Dept. Regn. 2011/2001/2009294

NAME: ANAND KUMAR

D/O ANIL KUMAR, J. P.

PH: 8121982144

HALL NO. PUN. DISTRICT - GAYA, BIHAR

55014

MBT. ID: 10358740570

Department

Dept. Code

Unit Code

Room No.

F/F

Days / Mon. (MORNING)

App. Date

12/09/2015

No.

Loc./Address

रिपोर्ट/Diagnosis

दिनांक/Date

उपचार/Treatment

83 12.9 Kg

Cycle 5 chemotherapy

Day 0 - Ij Cisplatin 83mg

Day 1 - 8p

Day 2 - Ij Daromycin 16.5 mg/100 ml NI over
1hr

Ij Etoposide 55mg

Day 3+4 Ij Cyclophosphamide 550mg

+
Mucic 200mg O, S, B, L.

Day 5 Ij Etoposide 55mg

- Cont supportive care

2

HB-8.5
TLC-4300
Plt-1771000
ANC-1.8

RT for cycloph
sister Kalia

अंगदान-जीवन का बहुमूल्य उपहार / ORGAN DONATION - A GIFT OF LIFE

O.R.B.O., AIIMS, 26588360, 26593444, www.orbo.org Helpline - 1060 (24 hrs service)

आपस से जुड़ने वाले रोगियों के लिए धर्मशाला की सुविधा अस्पताल ई/Dharamshala facility is available for outstation patients



अ० भा० आ० सं० अस्पताल / A.I.I.M.S. HOSPITAL बहिरंग रोगी विभाग / Out Patient Department

अस्पताल के अन्दर धूम्रपान मना है। / SMOKING PROHIBITED IN HOSPITAL PREMISES

POC 113/15⁴ OPR-6

एकव/Unit: 2015/003/0009294
विभाग/Dept: Paediatrics (बाल चिकित्सा विभाग) Unit-III

नाम/Name	पिता/पुत्र/पत्नी/पुत्री F/S/W/H/D of	लिंग Sex	वय Age	पता/Address
ANAND KUMAR	S/O: ANIL KUMAR	M पुरुष	2Y वर्ष महिला 32D दिल	KALYAN PUR, DISTT- GAYA, BIHAR, INDIA M: 9717848439

निदान/Diagnosis

दिनांक/Date	उपचार/Treatment
<p>Registration Time : 08:30 AM-10:30 AM Done By: Paediatrics Counter/312 Room No. 4, Ground Floor (तल मंजिल) 30/03/2015 09:00:00 AM</p> <p>*TO TAKE APPOINTMENT NUMBER THROUGH PHONE, DIAL: 011-265899-9 *श्रीर के माध्यम से अप्पॉइंटमेंट नंबर लेने के लिए, डायल : 011-26589999 **Doctors may not be available, however you may be seen by some of the doctors in the department ***आपके डॉक्टर के उपलब्ध न होने पर, आपकी विभाग में अन्य किसी डॉक्टर द्वारा देखा जा सकता है।</p>	<p>Fluc of Neomabestom due for cycle 2 No compleat at present.</p> <p>0/E PP @ CFT C3w HR - 100/w RA - 20/w PIA - left</p> <p><u>Adv</u> Cycle of clera</p> <p>I₁ cisplatin 33mg - Day 0 - aft. protocol Gap Day 1 I₁ Doxorubicin 16.5mg } Day 2 I₁ Etoposide 55mg</p>
<p>MB-101 TLL-7400 PI+ 37600.0 ANC-4.4</p> <p>Bm eni - No metastasis Bil - 0.3 O.T.I.P.T. 47/52</p>	



¹³¹I-MIBG WHOLE BODY SCAN

Patient Name: ANAND KUMAR

Age/Sex: 2y/M

Study ID: MIBG-D-50-640-15

Date: 10-6-2015

Indication: K/c/o Neuroblastoma

Findings:


Large area of abnormal increased radiotracer uptake noted in abdomen (approximately 9.1 x 8.7cm) consistent with Neuroblastoma.

Physiological radiotracer distribution seen in the salivary glands, myocardium, liver and urinary bladder.

Impression:

Scan findings suggestive of MIBG concentrating primary tumor in the abdomen consistent with Neuroblastoma.

No scan evidence of any metastases.


or Resident

Consultant

\checkmark I₁ Cyclophosphamide (1000 mg/m²) 550 mg bid for 3 days
 +
 Meve 200 mg qd 3, 6 hr

I₂ Etoposide 55 mg Day 5

+ Syb Enst 5ml TDS x 3 day

→ Continue supportive measure

Syb Septren 7.5ml BID

Syb Fe/FA 5ml OD

Syb Calcium 5ml OD

8 JUN 2015

Ans

(33)

18.9.2

No line computer

BC (g/Lts)

Hb = 9.5

Ht = 18.50

Hct = 0.7

Wt = 1.40

15/6/11

Hb = 8.7

TLC = 10,000

PLT = 83,000

ANC = 5.4

11/06

Hb = 8.3

TLC = 400

PLT = 73,000

ANC = 0.1

Advt to review E reports for next year

~~Review~~

No computer

Adv Risk of febrile neutropenia entered

→ I₁ GCSF 100 iu s.c OD x 5 d

- Stop GCSF

Ans

Department of Nuclear Medicine and PET-CT
All India Institute of Medical Sciences, New Delhi, India.



Patient Name: ANAND SHARMA

Age/Sex: 2Y/M

Study ID: MDP-49-5917-15

Date: 28-04-15

Indication: C/o abdominal mass under evaluation

^{99m}Tc – MDP WHOLE BODY BONE SCAN

Findings:

Heterogeneously increased tracer uptake seen in the abdominal region in the midline.

Rest of the skeleton shows normal tracer distribution.

Bilateral kidneys are visualized.

Impression:

- Heterogeneously increased tracer uptake seen in the abdominal region in the midline- primary tumor.
- No scan evidence of skeletal metastases.

Senior Resident

Consultant

to decide about further plan

$$\frac{4.9 \times 10^{-6}}{50}$$

2 S Agonals of use

~~VMA~~

VMA 4.0 ng/yrk
(2-6 yr/yr)

MIBY amount → 25/7/16

2 S Agonals of use

Thursday
9810590047

23/7/16

2w on S Agonals
but stable ; High melatonin
NB.

urgently & review

- VMA (P)
- MIBY amount

to follow MIBY
2 S Agonals - review
H

Thursday
9/8

Friday
10/8

POC-113/15

10



अ० भा० आ० सं० अस्पताल / A.I.I.M.S. HOSPITAL बहिरंग रोगी विभाग / Out Patient Department

अस्पताल के अन्दर धूम्रपान मना है। / SMOKING PROHIBITED

L PREMISES

OPR-6

बहिर्गम्य धूम्रपान मना है।

एम्ब/Unit

विभाग/Dept.

रोगी Name



CHD: 100905947

Dept. Regn. 2011/2001/2009294

NAME: ANAND KUMAR

D/O ANIL KUMAR, J. P.

PH: 8121982144

HALL NO. 105533 - GAYA, BIHAR

55014

Department

Dept: Radiotherapy

Unit: Unit-1

Room: 14

F/E

Days / Mon, Thu, (M-F)

App. Date:

14/09/2015

No.

Age/Address

MRN. ID:

10358740570

रिपोर्ट/Diagnosis

दिनांक/Date

उपचार/Treatment

8/3 12.9 Kg

Cycle 5 chemotherapy

Day 0 - Ij Cisplatin 83mg

Day 1 - 8cp

Day 2 - Ij Daromycin 16.5 mg/100 ml NI over
1hr

Ij Etoposide 55mg

Day 3+4 Ij Cyclophosphamide 550mg

+
Mucic 200mg O, S, 6L.

Day 5 Ij Etoposide 55mg

- Cont supportive care

2

HB-8.5
TLC-4300
Plt-1771000
ANC-1.8

RT for Cycle 5
Sister Kalia

अंगदान-जीवन का बहुमूल्य उपहार / ORGAN DONATION - A GIFT OF LIFE

O.R.B.O., AIIMS, 26588360, 26593444, www.orbo.org Helpline - 1060 (24 hrs service)

आपस से जुड़ने वाले रोगियों के लिए धर्मशाला की सुविधा अस्पताल ई/Dharamshala facility is available for outstation patients



DEPARTMENT OF RADIO-DIAGNOSIS
All India Institute of Medical Sciences (AIIMS)
Ansari Nagar, New Delhi - 110029

Patient Name: ANAND KUMAR Sex: M Age: 3Y
Patient ID: RAD103569 Report state: Signed-off
OPD/Ward: Pediatrics Unit 2/OPD
EXAMINATION DESCRIPTION: PERFORMED ON: CR No.:
CT WHOLE ABDOMEN (IV) 29 10 2015 11 56 100905947

Admitting diagnosis:

Known case of neuroblastoma, completed 5 cycles of chemotherapy

Previous scans done outside

Report:
CECT ABDOMEN

CT scan of the abdomen was performed with oral and IV contrast administration using 24x0.6mm collimation

A large heterogenous soft tissue attenuation mass of size approx. 9.3 x 4.9 x 9.8cm (MLXAPXCC) is noted in midline in retroperitoneal region extending from L1 to L5 vertebrae. Few hypodense areas and multiple coarse calcific foci are present within the mass. The mass is encasing the infrarenal aorta, inferior mesenteric artery, an accessory left renal artery without causing any narrowing in the calibre and displacing the IVC posterolaterally towards right. Small bowel loops are displaced anteriorly by the mass. prevertebral fat plane is maintained and no e/o any intraspinal extension is noted. Bilateral ureters are displaced laterally and no hydronephrosis is noted. Multiple small subcentimetric bilateral common iliac and external iliac lymph nodes are noted with calcification within, average size 7x5mm. Mild ascitis is present in left iliac fossa.

Liver is normal in size and attenuation. No focal lesion / IHBRD seen.

Hepatic veins and portal vein are normal.

Gall Bladder is normal, multiple calculi are present within the GB s/o cholelithiasis. CBD is not dilated.

Spleen is normal in size, shape and outlines. No focal lesion. Splenic vein is of normal calibre.

Pancreas is normal in size and attenuation. SMA and SMV are normal.

Both kidneys are normal in size, shape, outline and attenuation. No hydronephrosis or calculus.

Adrenals are normal.

Urinary Bladder is normal.

Bones are normal.

Sections obtained through lower chest are unremarkable.

Impression:

Known case of neuroblastoma on chemotherapy shows:

A large soft tissue attenuating retroperitoneal mass with internal calcifications and causing encasement of the infrarenal aorta, IMA and its branches as described with few calcified b/l external and common iliac lymph nodes with mid ascitis.

On comparison with previous CT dated 04/04/2015 done outside, there is mild reduction in the size of the mass and mass and the retroperitoneal lymph nodes shows calcification in the current scan.



अ० भा० आ० सं० अस्पताल / A.I.I.M.S. HOSPITAL
बहिरंग रोगी विभाग / Out Patient Department

अस्पताल में अन्दर धूम्रपान मना है। / SMOKING IS PROHIBITED IN HOSPITAL PREMISES

Regn. No. _____
पता / Address _____

DeptSeq: 265
Dept: Paediatrics
Unit: Unit-III
Room: 7
F/23
Days:
App. Date: 04/08/2016

OPR-6

Adpt. ID: 2016080400910

Diagnosis

Metastatic Neuroblastoma

Date

35/15/16

Treatment

Completed 6 cycles of chemo (22/1/16)
RT ✓

Upt of abd: mild increase in size of retroperitoneal mass (26/1/16)

Adv

- Review in POC clinic on Mon @ 9am

- Sup. Amoxicillin (500mg) 5ml TDS @ 8hrs
Zab

31/7/16 - Metastatic Neuroblastoma

- post 6 cycles of chemo & RT

- MZB4 - due -

- 24 hr vom y.no, resolution

- 24h - ① Rupted on ~~1st~~ 2nd day

CLEAN AND GREEN AIIMS / एम्स का यही संकल्प, स्वच्छता से काया कल्प

अंगदान-जीवन का बहुमूल्य उपहार / ORGAN DONATION - A GIFT OF LIFE

O.R.B.O., AIIMS, 26538360, 26593444, www.orbo.org Helpline - 1060 (24 hrs service)



अ० भा० आ० सं० अस्पताल / A.I.I.M.S. HOSPITAL
 बहिरंग रोगी विभाग / Out Patient Department

अस्पताल के अन्दर धूम्रपान मना है। / SMOKING PROHIBITED IN HOSPITAL PREMISES

बहिरंग विभाग

एकव/Unit: 2015/003/0009294
 विभाग/Dept: Paediatrics (बाल चिकित्सा विभाग) Unit-III
 नमूना संख्या सं०/O.P.D. Regn: UNID: 100905947

POC 113/15⁴ OPR-6

नाम/Name	पिता/पुत्र/पत्नी/पुत्री F/S/W/H/D of	लिंग Sex	वय Age	पता/Address
ANAND KUMAR	S/O: ANIL KUMAR	M पुरुष	2Y वर्ष महिला 32D दिल	KALYAN PUR, DISTT- GAYA, BIHAR, INDIA M: 9717848439

निदान/Diagnosis

दिनांक/Date	उपचार/Treatment
Registration Time : 08:30 AM-10:30 AM Done By: Paediatrics Counter/312 Room No. 4, Ground Floor (तल मंजिल) 20/03/2015 09:00:00 AM	Fluc of Neomablastone due for cycle 2 No consent at present
*TO TAKE APPOINTMENT NUMBER THROUGH PHONE, DIAL: 011-265899-9 *शुद्ध के माध्यम से अपॉइंटमेंट नंबर लेने के लिए, डायल: 011-26589999 **Doctors may not be available, however you may be seen by some of the doctors in the department ***आपके डॉक्टर के उपलब्ध न होने पर, आपकी विभाग में अन्य किसी डॉक्टर द्वारा देखा जा सकता है।	O/E PP @ CFT C3w HR - 100/w RA - 20/w P/A - left
Mb-101 TLL-7400 PI+ 37600.0 ANC-4.4	Adv Cycle of clera
BM eni - No metekull Bil - 0.3 O.T.P.T. 47/52	I ₁ cisplatin 33mg - Day 0 - aft. protocol Gap Day 1 I ₁ Doxorubicin 16.5mg } Day 2 I ₁ Etoposide 55mg



अ० भा० आ० सं० अस्पताल / A.I.I.M.S. HOSPITAL
बहिरंग रोगी विभाग / Out Patient Department

अस्पताल के अन्दर धूम्रपान मना है। / SMOKING PROHIBITED IN HOSPITAL PREMISES

12

OPR-6

एकता / Unit
विभाग / Dept.

नाम / Name



UNID: 100913947
Dept. Regn: 2011/001/0005294
Name: ANMO KUMAR
S/O ANIL KUMAR, 2Y SH 290 - H
Ph: 8521082344
KALYAN PUR - DISTT - GAYA, BIHAR
INDIA

Deptseq: 228
Dept: Paediatrics
Unit: UNIT-III
Room: 7
F/35
Days: Wed, Sat, Sun, Mon
App. Date: 07/10/2015

Regn. No.

पता / Address



Appt. ID: 2015100701558

रिपोर्ट / Diagnosis

AB

दिनांक / Date

34

CECT chest
RAD 103569.

उपचार / Treatment

13:30 5 cycles completed

- No fever/cough/runny nose.
- No complaint
- on AD reprim.
- was to get repeat CECT chest + Abdomen for response.

However, CECT chest only done (Abdomen not done)

cl. vitalb. stable
PR 98/min
RR 26/min

ADU

- ① CECT Abdomen to be done.
- ② Review with cect films for discussion.
- ③ Syp. Sertran 7ml AD

Maikla

~~531318~~
AD 103569
29/10

अंगदान-जीवन का बहुमूल्य उपहार / ORGAN DONATION - A GIFT OF LIFE

O.R.B.O., AIIMS, 26588300, 26593444, www.orbo.org Helpline - 1060 (24 hrs service)

हर से आने वाले रोगियों के लिए धर्मशाला की सुविधा उपलब्ध है / Dharamshala facility is available for outstation patients

Department of Nuclear Medicine and PET-CT
All India Institute of Medical Sciences, New Delhi, India.



Patient Name: Anand

Age/Sex: 2Yr/M

Study ID: RDS-50-9787-15

Date: 23-11-15

Indication:  Neuroblastoma

^{99m}Te-LLEC RENAL DYNAMIC SCAN

Findings:

Overall background activity is normal.

Left kidney:

- Normal size, shape and location.
- Shows normal perfusion and parenchymal radiotracer uptake with non obstructive clearance.

Right kidney:

- Normal size, shape and location.
- Shows normal perfusion and parenchymal radiotracer uptake with non obstructive clearance.

Differential function:

Left kidney	Right kidney
50%	50%

Impression:

- Normal functioning bilateral kidneys with non obstructive clearance.


Senior Resident

Consultant



DEPARTMENT OF RADIO-DIAGNOSIS
All India Institute of Medical Sciences (AIIMS)
Ansari Nagar, New Delhi - 110029

Patient Name: ANAND KUMAR Sex: M Age: 2Y
Patient ID: RAD103569 Report state: Signed-off
OPD/Ward: Pediatrics Unit3/OPD
EXAMINATION DESCRIPTION: PERFORMED ON: CR No.:
CT THORAX (CONTRAST) 06.10.2015 10 19

Admitting diagnosis:
Abdominal mass

Report:
CECT CHEST

CT scan of the chest was performed after i.v. contrast administration.

Both the lungs are normal.
Tracheobronchial tree is normal.
No significant mediastinal adenopathy is noted.
Heart and mediastinal vascular structures are normal.
No pleural or pericardial fluid is seen.
Bones are normal.
Scanned sections through upper abdomen show an enhancing retroperitoneal soft tissue mass lesion with foci of calcification.

Impression:
Normal study of CECT thorax.

Note: Retroperitoneal soft tissue mass.

Dr. Naveen J

Dr. Surabhi Vyas

Report Signed Date/Time

2015.10.06 16:04

This document was signed-off electronically!



¹³¹I-MIBG WHOLE BODY SCAN

Patient Name: ANAND KUMAR

Age/Sex: 2y/M

Study ID: MIBG-D-50-640-15

Date: 10-6-2015

Indication: K/c/o Neuroblastoma

Findings:


Large area of abnormal increased radiotracer uptake noted in abdomen (approximately 9.1 x 8.7cm) consistent with Neuroblastoma.

Physiological radiotracer distribution seen in the salivary glands, myocardium, liver and urinary bladder.

Impression:

Scan findings suggestive of MIBG concentrating primary tumor in the abdomen consistent with Neuroblastoma.

No scan evidence of any metastases.


or Resident

Consultant

4/5/17

Refractory NB.

On Irinotecan/Temozolamide (15/4-22/4/17)

Sotret (1/4 → 15/4)

CBC - 9/2.01/17

2nd cycle Sotret started on 1/5/17

(Chitab not brought)

Child well

Accepting food

Plan 2nd cycle ^{Topo} Irinotecan + Temozolamide
from 16/5/17 → 20/5/17.

CBC
LFT/RFT

from
16/5/17

- Cap Sotret (20mg) 2cap BD x 15d
- Cap Temozolamide 100mg OD x 5d
- Inj Topotecan 0.5mg IV OD x 5d
- Co-trimoxazole to continue

Alupha

16/5/17

Hb - 10.0

PLT - 171

WBC - 6.24

APU 4.61

Urea - 15

Cr - 0.3

PT/PTT - 26/12

ALP - 503

Alb - 0.2

CASH MEMO

TIN : 07750026492
D.L. No. : 16 (7) 20 & 21

Phone : 41516266
Telefax : 23327284
Cell : 9899441605

NATH BROTHERS
★ DISPENSING CHEMISTS ★

2G, MARINA ARCADE, CON. CIRCUS, NEW DELHI - 110 001
E-mail : nathbrothers@hotmail.com, nathbrothers1951@gmail.com
ALSO AVAILABLE SPECIAL INDIAN, IMPORTED,
LIFE SAVING, DRUGS AND SURGICALS

QTY.	PARTICULARS	VAT %	BATCH No.	EXP. DT.	AMOUNT
5	TEMICAD 100MG CAPS.##	5.0%	BTZCB702YA01/19		1,800.00
1	TOPOTEC 2.5 MG INJ.	5.0%	TOIK6A2	10/18	4,200.00

OPEN 10 A.M. To 9 P.M. (SUNDAY CLOSED)

CODEFREE+ METER WITH 200LANCET
& 50 STRIPS ONLY FOR *RS1500**

Amount Tendered 6,000.00 M.R.P Total 6,000.00
Balance Amount 0.00
Vat 5% on 5714.29: 285.71
Vat 12.5% 0.00: 0.00
6,000.00

THANK YOU! (VAT Paid) TOTAL

DATE: 18-Apr-2017
PATIENT Ms./Mr.: ANAND KUMAR
7368088388
PRESCRIBED BY Dr. RACHNA SETH

TIME:
BILL No.: 3858
5 SIGNATURE

★ Price are inclusive of all the taxes. ★ Goods once sold will not be taken back .
★ Please consult your doctor before using medicines.

Printed By : Pooja Impression
All Disputes are subject to Delhi Jurisdiction.

Ph: 911-26175933


RETAIL INVOICE / CASH MEMO

Pioneer Medicos

CHEMISTS & DRUGGIST

Shop No. 4/52, Gate No. 2, Safdarjung Hospital, New Delhi-110029
TIN: 07000156667, DL No. : S(1119) 13R

QTY	PARTICULARS	BATCH NO.	EXP. DT.	VAT%	AMOUNT
2	CALPOL 200MG SYR	A0170	07/18	5.0	20.50
1	SEDTRAX 50MG SYRUP	K3171	12/18	5.0	31.50
100	ROXET 200MG TAB	PH0027	10/18	5.0	1230.00



Some items will not be returned or exchanged
 Expired medicine can be returned with bill
 between 21:00pm with in two to three days.

PLEASE CONSULT YOUR DOCTOR
 BEFORE STARTING THE MEDICINE
THANKING YOU!

MRP TOTAL 1,332.00
 PAID AMT. 1,332.00

DATE 22/04/2017
 PATIENT Ms/Mr
 ADDRESS ANAND KUMAR
 PRESCRIBED BY Dr :

INVOICE No. : 18313
 TIME: 10:34AM

Terms & Conditions : Goods once sold will not be returned or exchanged.
 In case of any error in the price charged please bring this cash memo for refund of difference.

SIGNATURE

Provided by: www.pioneermedicos.com

TIN : 07750026492
D.L. No. : 16 (7) 20 & 21

CASH MEMO

Phone : 41516266
Telefax : 23327284
Cell : 9899441605

NATH BROTHERS

★ DISPENSING CHEMISTS ★

2G, MARINA ARCADE, CON. CIRCUS, NEW DELHI - 110 001
E-mail : nathbrothers@hotmail.com, nathbrothers1951@gmail.com
ALSO AVAILABLE SPECIAL INDIAN, IMPORTED,
LIFE SAVING, DRUGS AND SURGICALS

QTY.	PARTICULARS	VAT %	BATCH No.	EXP. DT.	AMOUNT
5	TEHEAD 100MG CAPS. ##	5.0%	702YA	01/19	1,800.00
1	TOPOTEC 2.5 MG INJ.	5.0%	70IK6A2	10/18	4,200.00

CODEFREE+ METER WITH 200LANCET
& 50 STRIPS ONLY FORMORS1500**

M.R.P Total 6,000.00

Vat 5% on 5714.29: 285.71

Vat 12.5% 0.00: 0.00

6,000.00

THANK YOU! (VAT Paid)

TOTAL

DATE: 16-May-2017

TIME:

PATIENT Ms./Mr.: ANAND

BILL No.: 10362

7368083385

PRESCRIBED BY Dr. RACHNA SETH

5 SIGNATURE

★ Price are inclusive of all the taxes. ★ Goods once sold will not be taken back .

★ Please consult your doctor before using medicines.

OPEN 10 A.M. To 9 P.M. (SUNDAY CLOSED)

All Disputes are subject to Delhi Jurisdiction.

POC:-113/15



अ० भा० आ० सं० अस्पताल / A.I.I.M.S. HOSPITAL
बहिरंग रोगी विभाग / Out Patient Department

अस्पताल के अन्दर धूम्रपान करना है। / SMOKING IS PROHIBITED IN HOSPITAL PREMISES

रोगी का नाम

OPR-6

एक/Unit
विभाग/Dept.

GENERAL
FO: 100905947
CLINIC NO: 1514/POC/113
NAME: ANAND DIXIT
S/O: ANIL KUMAR AG 250, M
PH: 7930 2300
KALKAJI, DELHI-110016, GAYA, BIHAR,
INDIA

Department: 564
Dept: Paediatrics
UNIT: Unit-3
Room: 14
F/30
Days: MON
App. Date: 01/05/2017

Regn. No./O.P.D. Regn. No.

Address

निदान/Diagnosis

दिनांक/Date

उपचार/Treatment

NO

Stage IV NB (Refractory)
(on Temozolamide & Tisipatecan)
↓
(last dose on 22/4/17)

CEL - Antel

(PABE infusandoc on 30/4/17)

ph: →

1) To check CBC.

2) R/v in (Cordycean 2/5/17)
(7-10 AM)

CLEAN AND GREEN AIIMS / एम्स का यही संकल्प, स्वच्छता से काया कल्प

अंगदान-जीवन का बहुमूल्य उपहार / ORGAN DONATION - A GIFT OF LIFE

O.R.B.O., AIIMS, 26588360, 26593444, www.orbo.org Helpline - 1060 (24 hrs service)



सत्यमेव जयते

भारत निर्वाचन आयोग
पहचान पत्र

ELECTION COMMISSION OF INDIA
IDENTITY CARD

TJG1103727



निर्वाचक का नाम अनिल कुमार

Elector's Name Anil Kumar

पिता का नाम हरिशचन्द्र प्रसाद

Father's Name Harishchandra
Prasad

लिंग /Sex पुरुष/Male

जन्म तिथि
Date of Birth

X	X	X	X	1	9	7	5
---	---	---	---	---	---	---	---

TJG1106707

पता : कुजापी
शहर/गाँव - कुजापी,
अंचल - नगर,
जिला - गया, 823002

Address : Kujapi
Town/Vill - Kujapi,
Anchal - Nagar,
Distt. - Gaya, 823002

दिनांक / Date : 30/9/2010

232,बेलागंज निर्वाचन क्षेत्र के निर्वाचक
रजिस्ट्रीकरण अधिकारी के हस्ताक्षर की अनुकृति

Facsimile Signature of Electoral Registration
Officer 232.Belaqani, Constituency

पता बदलने पर, नये पते पर अपना नाम निर्वाचक नामावली में
दर्ज करवाने तथा उस पते पर इसी नम्बर का कार्ड पाने के लिए
सम्बंधित फार्म में यह कार्ड नम्बर अवश्य लिखें

In case of change in address, mention this card
no. in the relevant form for including your name
in the roll at the changed address and to obtain
the card with the same number.

To,
Utham Trust
New Delhi / NCR

Sir, With great sorrow I want to inform you that my son Anand Kumar age - 4 years is suffering from Neuroblastoma cancer, he is in last stage of the disease. I have spent lot of Money for his treatment, and now I'm feeling that I won't be able to continue his treatment due to financial problems, bcoz Now his Medicines are too costly.

Kindly help me in my son's treatment, for that I would be grateful to you.

Yours faithfully
Anil Kumar

7368088388
Vill + P.O. → Kujapi
Distt: → Gaya
Bihar

CASH MEMO

TIN : 07750026492
D.L. No. : 16 (7) 20 & 21

Phone : 41516286
Telefax : 23327284
Cell : 9899441605

NATH BROTHERS
★ DISPENSING CHEMISTS ★

2G, MARINA ARCADE, CON. CIRCUS, NEW DELHI - 110 001
E-mail : nathbrothers@hotmail.com, nathbrothers1951@gmail.com
ALSO AVAILABLE SPECIAL INDIAN, IMPORTED,
LIFE SAVING, DRUGS AND SURGICALS

QTY.	PARTICULARS	VAT %	BATCH No.	EXP. DT.	AMOUNT
1	TEUCAD 100MG CAPS.##	5.0%	KITZER702YA01/19		1,800.00
1	TOPUTEC 2.5 MG INJ.	5.0%	101D7A1	03/19	4,200.00

OPEN 10 A.M. To 9 P.M. (SUNDAY CLOSED)

All Disputes are subject to Delhi Jurisdiction.

Printed By : Poola Impressions Pvt. Ltd Mob. : 9212383333, 8527524524

HAPPINESS OF YOUR LIFE DEPENDS ON THE QUALITY OF YOUR THOUGHTS

In Your Service M.R.P Total 6,000.00

Vat 5% on 5714.29: 285.71
Vat 12.5% 0.00: 0.00

CREDIT CARDS ACCEPTED

6,000.00

THANK YOU! (VAT Paid) TOTAL

DATE: 16-Jul-2017
PATIENT Ms./Mr. UTTAM TRUST ANAND
7053000938

TIME :
BILL No. : 17667

PRESCRIBED BY Dr. RACHANA SETH

SIGNATURE

★ Price are inclusive of all the taxes. ★ Goods once sold will not be taken back .
★ Please consult your doctor before using medicines.

Ph.: 011-26175037

RETAIL INVOICE / CASH MEMO

Pioneer Medicos

CHEMISTS & DRUGGIST

Shop No. S/52, Gate No. 2, Safdarjung Hospital, New Delhi-110029
TIN : 07660156667, DL No. : S(1119) 13R

QTY.	PARTICULARS	BATCH NO.	EXP. DT.	VAT%	AMOUNT
40	SOTRET 20MG CAP	PNR0020	07/18	5.0	820.00
20	SOTRET 20MG CAP	PNR0023	10/18	5.0	410.00



Fridge ITEMS Will Not Be Returned or changed
Unused medicine can be returned with bill
between 2to5pm with in two to three days.

**PLEASE CONSULT YOUR DOCTOR
BEFORE STARTING THE MEDICINE
THANKING YOU!**

MRP TOTAL 1,230.01
PAID AMT. 1,230.00

DATE 24/05/2017

INVOICE No. 33101

PATIENT Ms./Mr. : ANAND KUMAR

Time: 2:08PM

PRESCRIBED BY Dr. :

Terms & Conditions : Goods once sold will not be returned or exchanged.
In case of any error in the price charged please bring this cash memo for refund of difference.

SIGNATURE



स्त्रीरवाद्यं चतुर्धर्मतामनम्

अ० भा० आ० सं० अस्पताल / A.I.I.M.S. HOSPITAL
बहिरंग रोगी विभाग / Out Patient Department

अस्पताल के अन्दर धूम्रपान मना है। / SMOKING IS PROHIBITED IN HOSPITAL PREMISES


एकक / Unit _____

विभाग / Dept. _____

नाम / Name

General

Consultation Time: 11.00 AM-01.00 PM



DeptSeq: 235

UHID: 100905947
Dept. Regn. 2015/003/0009294

Dept: Paediatrics

Name: ANAND KUMAR
S/O ANIL KUMAR, 4Y 2M 20D, M

Unit: Unit-III

Ph: 7368088388

Room: 7

KALYAN PUR, DISTT- GAYA, BIHAR,
INDIA

Days: wed, Sat (बुध, शनि)

App. Date:
28/06/2017

Appt. ID:



2017062313897

OPR-6

gn. No. _____

पता / Address

निदान / Diagnosis

दिनांक / Date

उपचार / Treatment

(25)
(A)

stage IV NB.

On Irinotecan / Temozolamide

CBC - 7.4 / 10.1 / 214
0.62

MIBG scan.

Rev c report

CBC

Ri

CLEAN AND GREEN AIIMS / एम्स का यही संकल्प, स्वच्छता से काया कल्प

अंगदान-जीवन का बहुमूल्य उपहार / ORGAN DONATION - A GIFT OF LIFE

O.R.B.O., AIIMS, 26588360, 26593444, www.orbo.org Helpline - 1060 (24 hrs service)



अ० भा० आ० सं० अस्पताल / A.I.I.M.S. HOSPITAL
 बहिरंग रोगी विभाग / Out Patient Department

अस्पताल के अन्दर धूम्रपान मना है। / SMOKING IS PROHIBITED IN HOSPITAL PREMISES

General Consultation Time: 11.00 AM-01.00 PM
 DeptSeq: 235
 PO UHID: 100905947
 Dept: Paediatrics
 Dept. Regn. 2015/003/0009294
 Unit: Unit-III
 Name: ANAND KUMAR
 Room: 7
 S/O ANIL KUMAR, 4Y 2M 20D, M
 F/17
 Ph: 7368088388
 Days: Wed, Sat (बु, शनि)
 KALYAN PUR, DISTT- GAYA, BIHAR, INDIA
 App. Date: 28/06/2017
 Appt. ID: 2017062313897

OPR-6

gn. No. _____

पता/Address _____

निदान/Diagnosis

दिनांक/Date

उपचार/Treatment

25

stage IV NB.

(A)

On ^{Topo} ~~irinotecan~~ / Temozolamide

CBC - 7.4 | 1.1 | 214
 0.62

MIBG scan.

Rev c report

Rel.

CBC

General Consultation Time: 11.00 AM-01.00 PM
 DeptSeq: 201
 PO UHID: 100905947
 Dept: Paediatrics
 Dept. Regn. 2015/003/0009294
 Unit: Unit-III
 Name: ANAND KUMAR
 Room: 7
 S/O ANIL KUMAR, 4Y 2M 27D, M
 F/11
 Ph: 7368088388
 Days: Wed, Sat (बु, शनि)
 KALYAN PUR, DISTT- GAYA, BIHAR, INDIA
 App. Date: 05/07/2017
 Appt. ID: 2017062812636

CBC = 7.3 | 1.7 | 160
 0.4
 Post 3rd cycle { Temozolamide
 Topotecan

MIBG on 10th ?

Cap solut to continue

Rev c MIBG

Rev - sys Maxilia 7.5ml PO TDS - 5d

Rel.

30

CBC

Child stable:

CLEAN AND GREEN AIIMS / एम्स का यही संकल्प, स्वच्छता से काया कल्प

अंगदान-जीवन का बहुमूल्य उपहार / ORGAN DONATION - A GIFT OF LIFE

O.R.B.O., AIIMS, 26588360, 26593444, www.orbo.org Helpline - 1060 (24 hrs service)

POC:-113/15



अ० भा० आ० सं० अस्पताल/A.I.I.M.S. HOSPITAL
बहिरंग रोगी विभाग /Out Patient Department

अस्पताल के अन्दर धूम्रपान मना है।/SMOKING IS PROHIBITED IN HOSPITAL PREMISES

सर्वोपचार अनुसंधान

OPR-6

General Clinic No: POC-2014/POC/113 Name: ANAND KUMAR S/O ANIL KUMAR, 4Y 23D, M Ph: 7368088388 KALYAN PUR, DISTT- GAYA, BIHAR, INDIA	DeptSeq: 564 Dept: Paediatrics Unit: Unit-I Room: 14 F/30 Days: MON App. Date: 01/05/2017	Inpt No./O.P.D. Regn. No. Name/Address
Appt. ID: 2017050103834		

निदान/Diagnosis

दिनांक/Date

उपचार/Treatment

46

Stage IV NB (refractory)
(on Temozolamide & Tbspicean)
↓
(last dose on 2/4/17)

CSF - Anitcl

(Pre-infusion dose on 3/4/17)

Plan: →

- 1) To do CBC.
- 2) R/v in (C/dycean 2/5/17)
(7-10 Apr)

CLEAN AND GREEN AIIMS / एम्स का यही संकल्प, स्वच्छता से काया कल्प

अंगदान-जीवन का बहुमूल्य उपहार/ORGAN DONATION - A GIFT OF LIFE

O.R.B.O., AIIMS, 26588360, 26593444, www.orbo.org Helpline - 1060 (24 hrs service)

UHID: 100905947 Sample No: HMI-240317091
Name: Mr. ANAND KUMAR, Male Lab Ref No : 091
Ward Name: C5 DAY CARE Verification Time: 24/05/2017 12:19 pm

Report

Test Name	Result	Comment	Normal Range
WBC	2.67 $10^3/\mu\text{L}$		• 4 - 11 $10^3/\mu\text{L}$ 0Y - 100Y (A)
ANC	0.77 $10^3/\mu\text{L}$		• 2 - 7 $10^3/\mu\text{L}$ 0Y - 100Y (A)
HB	8.6 g/dL		• 13 - 17 g/dL 0Y - 100Y (M)
HCT	26.4 %		• 40 - 50 % 0Y - 100Y (M)
PLATELET	110 $10^3/\mu\text{L}$		150.00-400.00
RBC	3.49 $10^6/\mu\text{L}$		4.50-5.50

Over All Comment :

Authorised Signatory

Verified By
dharmnathirch

UHID:	100905947	Sample No:	HMI-200617106
Name:	Mr. ANAND KUMAR, Male	Lab Ref No :	423
Ward Name:	C5 DAY CARE	Verification Time:	20/06/2017 01:44 pm

Report

Test Name	Result	Comment	Normal Range
TLC	4.69 $10^3/\mu\text{L}$		• 4 - 11 $10^3/\mu\text{L}$
ANC	1.57 $10^3/\mu\text{L}$		• 2 - 7 $10^3/\mu\text{L}$
HB	9.1 g/dL		• 13 - 17 g/dL
HCT	28.2 %		• 40 - 50 %
PLATELET	374 $10^3/\mu\text{L}$		150.00-400.00

Over All Comment :

Authorised Signatory

Verified By
navinnsharma

UHID: 100905947
Name: Mr. ANAND KUMAR, Male
Ward Name:

Sample No: HMI-280617175
Lab Ref No : 175
Verification Time: 28/06/2017 01:43 pm

Report

Test Name	Result	Comment	Normal Range
TLC	1.12 10 ³ /μL		• 4 - 11 10 ³ /μL
ANC	0.62 10 ³ /μL		• 2 - 7 10 ³ /μL
HB	7.4 g/dL		• 13 - 17 g/dL
HCT	25.4 %		• 40 - 50 %
PLATELET	214 10 ³ /μL		150.00-400.00
RBC	3.33 10 ⁶ /μL		4.50-5.50

Over All Comment :

Authorised Signatory

Verified
navinnshar

UHID: 100905947 Sample No: HMI-050717063
 Name: Mr. ANAND KUMAR, Male Lab Ref No : 063
 Ward Name: Verification Time: 05/07/2017 12:02 pm

Report

Test Name	Result	Comment	Normal Range
TLC	1.74 $10^3/\mu\text{L}$		• 4 - 11 $10^3/\mu\text{L}$
ANC	0.42 $10^3/\mu\text{L}$		• 2 - 7 $10^3/\mu\text{L}$
HB	7.3 g/dL		• 13 - 17 g/dL
HCT	24.3 %		• 40 - 50 %
PLATELET	160 $10^3/\mu\text{L}$		150.00-400.00

Over All Comment :

Authorised Signatory

Verified By
navinnsharma



अ० भा० आ० सं० अस्पताल / A.I.I.M.S. HOSPITAL
बहिरंग रोगी विभाग / Out Patient Department

HOSPITAL PREMISES

संस्थान का नाम / Institution Name

एकांक / Unit

विभाग / Dept.

नाम / Name

General



UHID: 100905947
Dept. Regn. 2015/003/0009294

Name: ANAND KUMAR
S/O ANIL KUMAR, 4Y 1M 16D, M

Ph: 7368088188
KALYAN PUR, DISTT- GAYA, BIHAR, INDIA

DeptSeq: 446

Dept: Paediatrics
Unit: Unit-III

Room: 7
F/32

Days: Wed, Sat (रु, शनि)

App. Date: 24/05/2017

OPR-6

/O.P.D. Regn. No.

Address

ADPT. ID:



2017052404621

निदान / Diagnosis

दिनांक / Date

उपचार / Treatment

45

- Cycle 2 ✓
- Child & brought
- pregnancy confirmed
- new before 3rd cycle
- CBC
- EFT.

wants to go home ✓

railway
over
M-

near

CLEAN AND GREEN AIIMS / एम्स का यही संकल्प, स्वच्छता से काया कल्प

अंगदान-जीवन का बहुमूल्य उपहार / ORGAN DONATION - A GIFT OF LIFE

O.R.B.O., AIIMS, 26588360, 26593444, www.orbo.org Helpline - 1060 (24 hrs service)

(10 to 10:30 am) 28 JUNE 2017
2017062313897



अ० भा० आ० सं० अस्पताल / A.I.I.M.S. HOSPITAL
बहिरंग रोगी विभाग / Out Patient Department

SMOKING IS PROHIBITED IN HOSPITAL PREMISES

General



UMID: 100905947
Clinic No: P.ONCOLOGY OPD -
2016/P.ONCOLOGY OPD /43
Name: ANAND KUMAR
S/O ANIL KUMAR, JY 11N 27D, M
PH: 9431416181


DeptSeq: 408
Dept: Paediatrics
Unit: Unit-222
Room: 7
F/35
Days: WED, SAT
App. Date: 05/04/2017

OPR-6

1 No./O.P.D. Regn. No.

Address

Appt. ID:



2017040605744

निदान / Diagnosis

Relap Refractory stage IV NR

दिनांक / Date

उपचार / Treatment

Details in prev card dated 1/4/17.

Rx.

- Cap Temozolamide 100mg OD x 5d } for 13/4/17
(150mg/m²/day)
- Inj Topotecan 0.5mg IV OD x 5d. }
- Cap Sotret (20mg) 2 cap BD x 10d
- Septtrin to contin Hy.

Thursday
2pm

6/4/17 Uncle (Rakesh).
~~Father~~ explained about prognosis
stage IV → Refractory → Poor chances.
Side effects explained.
(Unlikely to respond but given as a
trial.).

Child having pain. (not responsive to heroin/
Utracet)

↓
Ref to Palliative Clinic Oncology (IRCH)

Dr S. Patny.
(May need Morphine) (60) - Pain chnc.
Hy.

CLEAN AND GREEN AIIMS / एम्स का यही संकल्प, स्वच्छता से काया कल्प

अंगदान-जीवन का बहुमूल्य उपहार / ORGAN DONATION - A GIFT OF LIFE

O.R.B.O., AIIMS, 26588360, 26593444, www.orbo.org Helpline - 1060 (24 hrs service)

CASH MEMO

TIN : 07750026492
D.L. No. : 16 (7) 20 & 21

Phone : 41516266
Telefax : 23327284
Cell : 9899441605

NATH BROTHERS

★ DISPENSING CHEMISTS ★

2G, MARINA ARCADE, CON. CIRCUS, NEW DELHI - 110 001
E-mail : nathbrothers@hotmail.com, nathbrothers1951@gmail.com

ALSO AVAILABLE SPECIAL INDIAN, IMPORTED,
LIFE SAVING, DRUGS AND SURGICALS

QTY.	PARTICULARS	VAT %	BATCH No.	EXP. DT.	AMOUNT
40	SOTRET 20MG CAPS.	5.00	PNR0026	10/18	820.00
20	SOTRET 20MG CAPS.	5.00	PNR0027	11/18	410.00

OPEN 10 A.M. To 9 P.M. (SUNDAY CLOSED)

E.&O.E.

In Your Service Since 1950

HAPPINESS OF YOUR LIFE DEPENDS
ON THE QUALITY OF YOUR THOUGHTS

Amt Tendered 1.230.00

Balance Amt 0.00

THANK YOU! (VAT Paid)

TOTAL

1.230.00

DATE: 30/06/2017

TIME:

PATIENT Ms./Mr. : ANAND KUMAR

BILL No. : 20650

7368088388

PRESCRIBED BY Dr. AIIMS

SUPER USER

SIGNATURE

★ Price are inclusive of all the taxes. ★ Goods once sold will not be taken back .

★ Please consult your doctor before using medicines.

All Disputes are subject to Delhi Jurisdiction.

Printed By : Pooja Impressions Pvt. Ltd. Mob. : 9212383333, 8527524524

UHID: 100905947 Sample No: HMI-180717147
Name: Mr. ANAND KUMAR, Male Lab Ref No : 147
Ward Name: Verification Time: 18/07/2017 01:54 pm

Report

Test Name	Result	Comment	Normal Range
TLC	3.11 $10^3/\mu\text{L}$		• 4 - 11 $10^3/\mu\text{L}$
ANC	1.18 $10^3/\mu\text{L}$		• 2 - 7 $10^3/\mu\text{L}$
HB	9.1 g/dL		• 13 - 17 g/dL
HCT	32.9 %		• 40 - 50 %
PLATELET	192 $10^3/\mu\text{L}$		150.00-400.00
RBC	3.95 $10^6/\mu\text{L}$		4.50-5.50

Over All Comment :

Authorised Signatory

Verified By
navinnsharma



प्रयोगशाला कायचिकित्सा विभाग
DEPARTMENT OF LABORATORY MEDICINE
नैदानिक रसायनिक
CLINICAL CHEMISTRY
अखिल भारतीय आयुर्विज्ञान संस्थान, अंसारी नगर, नई दिल्ली-110029
All India Institute of Medical Sciences, Ansari Nagar, New Delhi-110029
रक्त रसायन / BLOOD CHEMISTRY

UHID: 100905947 Sample No: CH-1807171007
Name: Mr. ANAND KUMAR, Male Lab Ref No : 774
Ward Name: Verification Time: 18/07/2017 06:39 pm

Report

Test Name	Result	Comment	Normal Range
UREA	16 mg/dL		10.00-40.00
CREATININE	0.2 mg/dL		0.50-1.00
CALCIUM	9.6 mg/dL		8.50-10.50
PHOSPHATE	4.6 mg/dL		2.50-4.50
URIC ACID	4.5 mg%		• 3.5 - 7 mg/dL
SODIUM	137 mEq/L		135.00-145.00
POTASSIUM	4.3 mEq/L		3.50-5.00
BILIRUBIN TOTAL	0.1 mg/dL		0.20-1.20
TOTAL PROTEIN	7.1 g/dL		6.00-8.00
ALBUMIN	4.8 g/dL		3.50-5.00
GLOBULIN	2.3 g/dL		2.00-3.50
SGOT (AST)	28 U/L		5.00-40.00
SGPT (ALT)	14 U/L		5.00-45.00
ALK PHOS (ALP)	507 IU/L		• 240 - 840 IU/L

Over All Comment :

Authorised Signatory
Dr.SudipKumarDatta

Verified By
sudhanshu

15/17

CSIBSR Mysore

KICCO ~~Aditya~~ RP - anobias
c/o Pain Abdomen Stayed

vomiting

initially nonbilious

Onxiodelast night? Yellow green

on chemo since last IV Ulyan
SP - Recontact.

0/5f

PIA - 20 GT
mild distended.

SP - f

CECW

Aditya

X-ray Abd -

no A-flexy

- NPO
- NGC on cont of x-ray (V = N) 2H do
- JUF, 2x antibiotics
- glycerine ~~enema~~ syringing
- (20+20ml), PR stat.

8.10pm - c/D/W Dr. Aditya Sir - gastro beds available

4b/- 8.8 TCC 48W N76 Put 50L - 92

US 4abd - RP - node 2.5cm. No mass

NO bed one available arranged in as post/now/now/now ^{gk} _{stems}

16b - - cont NPO part
- Access to Sategorgans hospital
MP

ABLE
PAT
1/1

Report Printout

Validated

report date: 05/08/2017 07:20:28 PM
 Sample ID: AUTO_SID158
 Collection Date:
 Department:
 Physician:
 Patient Name: ANAND
 First Name:
 Age: 4Y
 Gender: Male
 Operator: Technician

				<	Range	>	Flags and Alarms
RBC	3.43	L	10 ⁹ /mm ³	4.10	5.50		Remarks
HGB	8.8	L	g/dL	12.0	14.0		RBC of the Run 05/08/2017 07:20:27 PM
HCT	25.3	L	%	36.0	44.0	PM	WBC of the Run 05/08/2017 07:20:27
MCV	74		µm ³	73	89		PLT of the Run 05/08/2017 07:20:27 PM
MCH	25.6		pg	24.0	30.0		DIFF of the Run 05/08/2017 07:20:27 PM
MCHC	34.6		g/dL	32.0	36.0		
RDWcv	17.4	H	%	11.0	16.0		
RDWsd	46		µm ³	39	52		
PLT	588	H	10 ³ /mm ³	200	400		

WBC	4.8	L	10 ³ /mm ³	5.0	15.0		
	%		#	<	%	Range	# >
NEU	76.8		3.71	0.0	99.9	1.50	8.50
LYM	10.0		0.48	L	0.0	99.9	2.00
MON	11.3		0.55		0.0	99.9	0.00
EOS	1.7		0.08		0.0	99.9	0.00
BAS	0.2		0.01		0.0	99.9	0.00
ALY	1.1		0.05		0.0	2.5	0.00
LIC	0.5		0.02		0.0	3.0	0.00

Blood Gas Values

pH	7.414		[-]
pO ₂	36.2	mmHg	[-]
pCO ₂	34.6	mmHg	[-]

Temperature Corrected Values

pH(T)	7.414		
pO ₂ (T)	36.2	mmHg	
pCO ₂ (T)	34.6	mmHg	

Oximetry Values

ctHb	8.4	g/dL	[-]
sO ₂	64.0	%	[-]
FO ₂ Hb	62.0	%	
FMetHb	1.8	%	
FCOHb	1.4	%	
FHHb	34.8	%	

Electrolyte Values

cNa ⁺	126	mmol/L	[-]
↓ cK ⁺	3.4	mmol/L	[3.5 - 4.5]
cCa ²⁺	0.91	mmol/L	[-]
cCl ⁻	99	mmol/L	[-]

Metabolite Values

cGlu	96	mg/dL	[-]
cLac	0.7	mmol/L	[-]
↓ cCrea	0.31	mg/dL	[0.50 - 1.80]

Acid Base Status

cHCO ₃ ⁻ (P) _c	21.7	mmol/L
cHCO ₃ ⁻ (P,st) _c	22.3	mmol/L
ABE _c	-2.0	mmol/L
SBE _c	-2.2	mmol/L

Calculated Values

Anion Gap _c	5.0	mmol/L
AnionGap,K ⁺ _c	8.5	mmol/L
cCa ²⁺ (7.4) _c	0.92	mmol/L
ctCO ₂ (B) _c	46.3	Vol%
ctCO ₂ (P) _c	51.0	Vol%
Hct _c	26.1	%
p50 _c	29.25	mmHg
mOsm _c	256.9	mmol/kg
cH ⁺ _c	38.6	nmol/L
ctO ₂ _c	7.3	Vol%
pH(st) _c	7.369	

Notes

- ↓ Value(s) below reference range
 c Calculated value(s)

अखिल भारतीय आयुर्विज्ञान संस्थान, नई दिल्ली-110029

(REVISION)

ALL INDIA INSTITUTE OF MEDICAL SCIENCES, NEW DELHI -110029

आपातकालीन विभाग

(DEPT. OF EMERGENCY MEDICINE)



UHID No:100905947

आपातकालीन नं. (Emergency No): 2017/030/0090139

दिनांक DATE: 05/08/2017

समय TIME: 05:17:04 PM

NON-MLC

नाम NAME: MR. ANAND KUMAR आयु AGE: 4 years 3 months 27 days लिंग/SEX: M
 S/O: ANIL KUMAR
 पता ADDRESS: मकान संख्या H.NO: KALYAN PUR, DISTT- GAYA गली / मुहल्ला STREET/MOH:
 शहर/प्रखंड CITY/BLOCK: पिन PIN:
 राज्य STATE: BIHAR दूरभाष सं. PHONE NO:
 मोबाइल MOBILE NO: 7368088388 स्थान Location: Paediatrics Emergency
 द्वारा BROUGHT BY: Relative: FATHER Criticality: Red / Yellow / Green

Triage: Responsive/ Unresponsive HR /min BP mmHg RR /min spO2 %
 Shifted to Paeds/ Main/ New Emergency

Presenting Complaints

F/U/c/o Neuroblastoma

Clw Pain abdomen. } x 1 day.
Vomiting

Pain + in all quadrants

tenderness + in RIF.

Primary Assessment (ABCDE) : Assessment Pentagon

Airway Open & stable: Yes/No If No..... Breathing: RR/min Efforts: Normal/Poor/increased Auscultation: Air entry: Normal/poor/Differential Added sounds: None/Stridor/Wheeze/Crackles SpO2 on Room air.....98%	Circulation HR.....110/min CFT.....secs. 2sec BP.....104/70 mmHg Peripheral pulse: Poor/Good Central pulse: Poor/Good Skin temp: Warm/cool Others	Disability GCS.....15/15 Pupil size.....2mm/min Pupillary Reactions.....ESRL Motor activity: Normal & Symmetrical/Asymmetrical/ Posturing/Flaccidity/Seizure Blood Sugar.....mg/dl Exposure: Temp..... Colour: Normal/pallor/cyanosis /mottled Any other skin lesions.....
---	---	---

Diagnosis

CID/w Dr A. Gupta Sr.

Plan NPO

20 LVE N₂ ST dextrose, 400 ml of 8% (1:1000) Red Sx O/V.

USG abdomen no o/o obstruction/appendicitis
CBC, VBG,) any lab Red Sx

2mg Emset 4mg iv stat SOS

2mg Buscopan 15 mg iv stat.

2mg Panobrazole 15 mg iv stat

15kg

Dr.

नाभिकीय चिकित्सा विभाग
DEPARTMENT OF NUCLEAR MEDICINE
अखिल भारतीय आयुर्विज्ञान संस्थान
ALL INDIA INSTITUTE OF MEDICAL SCIENCES
नई दिल्ली-११००२९ / New Delhi-110029
TELEPHONE : 26864851 Ext.: 3210 (Direct Line 26593210)

नाम Anand Kumar आयु/लिंग
Name: Anand Kumar Age/Sex: 4/M

OPD/Indoor :

Investigation MIBG (r) whole

1. Deposit Rs. 27275/- at the Central Admission & Enquiry Office
2. Report at Room No. 59A on Try on at 9.00 A.M.
3. For DRCG do not pass Urine from 8.00 A.M.
4. For Gall Bladder imaging No food after 10.00 P.M.
5. For Renal dynamic study take plenty of water before study (at least 2 glasses)
6. The study may take entire day

2
Signature

Please collect your report from Room No. 54 on any working day between 10.00 A.M. to 4.00 P.M. except Tuesday and Saturday.

Name :
Investigation

Scan No. :
Date :

Note : Please Bring all your Medical Records alongwith you.

Signature

ALL INDIA INSTITUTE OF MEDICAL SCIENCES (AIMS) NEW DELHI

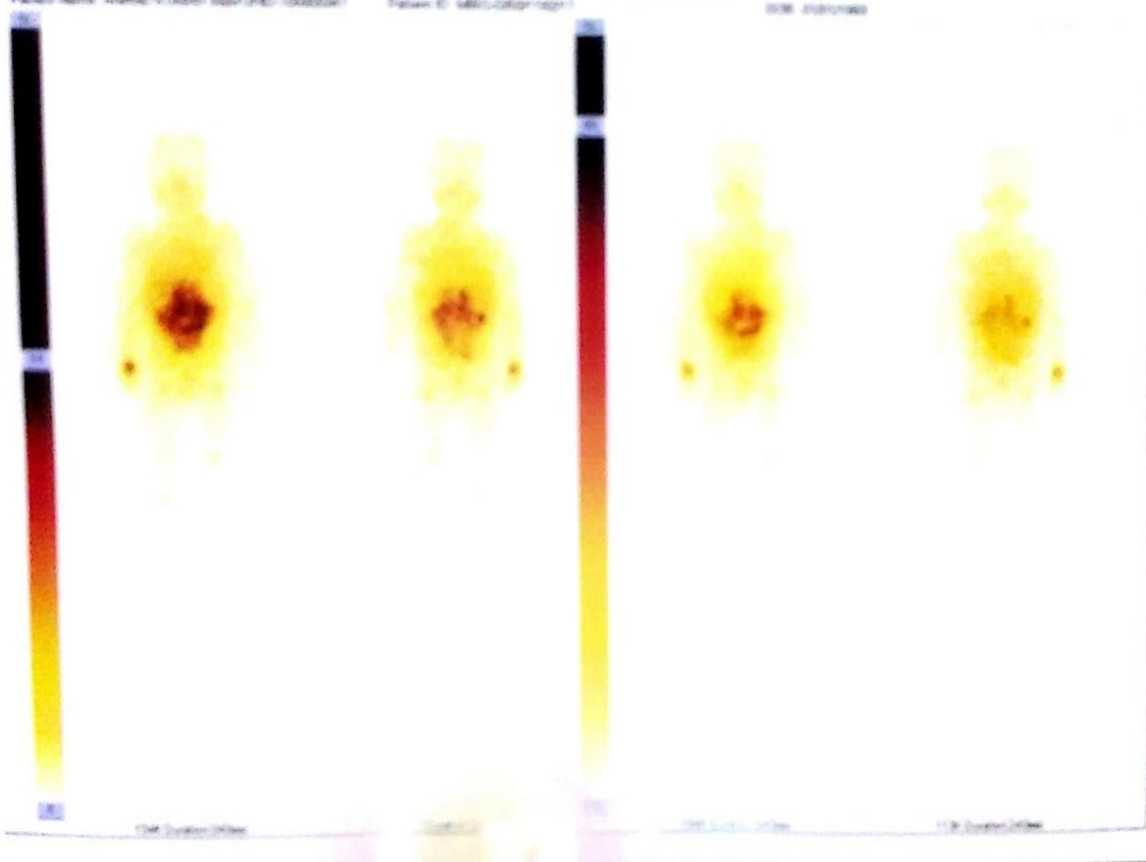
ASANO KUMAR [REDACTED] 204 24011985 M MISCORRECTED SEX W

STUDY NAME STUDY DATE 24/08/2017

Patient Name ASANO KUMAR [REDACTED]

Patient ID [REDACTED]

DOB 24/01/1985





अ० भा० आ० सं० अस्पताल/A.I.I.M.S. HOSPITAL
बहिरंग रोगी विभाग /Out Patient Department

अस्पताल में धूम्र उपहान मना है।/SMOKING IS PROHIBITED IN HOSPITAL PREMISES

General Consultation Time: 11:00 AM-01:00 PM

NO. UNED: 100905947 DeptSeq: 256

Dept. Regn. 2015/003/0009294 Dept: Paediatrics

Name: ANAND KUMAR Unit: Unit-III

S/O ANIL KUMAR, 4Y 4M 18D, M Room: 7

PH: 7168088388 Days: Wed, Sat (Su, Mo)

KALIAN PUR, DISTT- GAYA, BIHAR, INDIA

App. Date: 28/08/2017

Appt ID: 7017082214300

OPR-6

n. No. _____

पता/Address _____

एकक/Unit _____
विभाग/Dept. _____
नाम/Name _____

निदान/Diagnosis

Stage IV NB

उपचार/Treatment

MIBG → s/o progressive metastatic disease
D/w Dr R cell
To Options and progress explained
+ review on Monday. *Li*

28/8/17

Uncle has been explained about poor
progress
still wants some form of treatment

- Ref to Dr C S Bal for MIBG therapy date.
- *Li*

CLEAN AND GREEN AIIMS / एम्स का यही संकल्प, स्वच्छता से काया कल्प

अंगदान-जीवन का बहुमूल्य उपहार/ORGAN DONATION - A GIFT OF LIFE
O.R.B.O., AIIMS, 26588360, 26593444, www.orbo.org Helpline - 1060 (24 hrs service)

Department of Nuclear Medicine and PET-CT
All India Institute of Medical Sciences, New Delhi, India.



¹³¹I-MIBG WHOLE BODY SCAN

Patient Name: Anand Kumar

Age/Sex: 4yrs/M

Study ID: MIBG-D- SP-50-1182-17

UHID- 100905947

Date: 24-08-17

Indication: F/u/c of Neuroblastoma, post chemotherapy

Findings:

- Large area of heterogenous uptake noted in central abdomen.
- Mild focal areas of increased radiotracer uptake is seen in the bilateral femora.
- Physiological radiotracer distribution seen in the salivary glands, myocardium, liver and urinary bladder.

SPECT-CT:

- Previously noted heterogeneous soft tissue mass shows an increase in size measuring (11 X6.8 cm) [previous size (10.8x6.1cm)] involving almost whole of abdomen encasing retroperitoneal vessels with foci of calcification pushing bowels laterally and anteriorly.

Impression:

- Findings suggestive of MIBG concentrating lesion involving almost whole of abdomen.
- As compared to the previous scan (MIBG-D-50-929-16), there is an increase in size of the primary lesion with additional skeletal lesions involving the bilateral femora - s/o progressive disease.

Senior Resident

Consultant